



Tracheomalacia in Adults: An Uncommon Cause of Dyspnea

Natalie M. Yousef M.S. (OMS-II), Yusur Alsalihi B.A. (OMS-IV), Sundeep Grewal DO, Benjamin Teitelbaum MD

BACKGROUND

- **Tracheomalacia (TM)** is the most common congenital tracheal defect¹ due to developing, weak cartilage and a shorter trachea. It is rarely encountered in adults, often secondary to various risk factors. Here, we present a case of TM leading to stridor and dyspnea in an adult male.
- **Pathogenesis:** Normally, the intrathoracic trachea is compliant, dilating with inspiration and narrowing with expiration due to the difference between intrathoracic and intraluminal pressures¹⁻³. Most cases are expiratory - indicating excessive trachea narrowing when intrathoracic pressure is substantially greater than intraluminal pressure, as during forced expiration, cough, or the Valsalva maneuver⁴.
- **Epidemiology:** TM in the adult population is typically due to an acquired injury or chronic lung disease. Intubation injuries, chronic compression due to goiter or recurrent infections are some of the common causes of TM in adults. This occurs most commonly in the middle-aged and elderly, mostly in men >40 years of age⁵.
- **Diagnosis:** Bronchoscopic visualization of collapse remains the gold standard for diagnosing TM.

CASE PRESENTATION

- **HPI:** A 67-year-old man presents to the outpatient clinic with hoarseness, stridor, and shortness of breath ongoing for two years, as well as an intermittent dry cough. Patient denies dysphagia and nasal congestion. Patient underwent flexible laryngoscopy which revealed soft biphasic stridor with no other abnormal findings and was referred for a CT trachea scan.
- **PMH:** Hyperlipidemia, Hypertension, Diabetes Mellitus II.
- **Social History:** Smokes average of ½ pack a day (15 pack years). Two alcoholic beverages per week.
- **Physical Exam Findings:**
 - **Head** – Normocephalic & atraumatic. Hair is of normal texture and evenly distributed.
 - **Eyes** – Visual acuity is intact. Conjunctivae are clear. EOM are intact, PERRLA. No signs of nystagmus.
 - **Ears** – The pinna, tragus, and ear canal are non-tender and without swelling. The ear canal is clear without discharge. The tympanic membrane is intact.
 - **Nose** – Nasal mucosa is pink and moist. Nares are patent bilaterally.
 - **Throat:** Expiratory stridor noted. Could not visualize larynx and pharynx due to hyperactive gag.

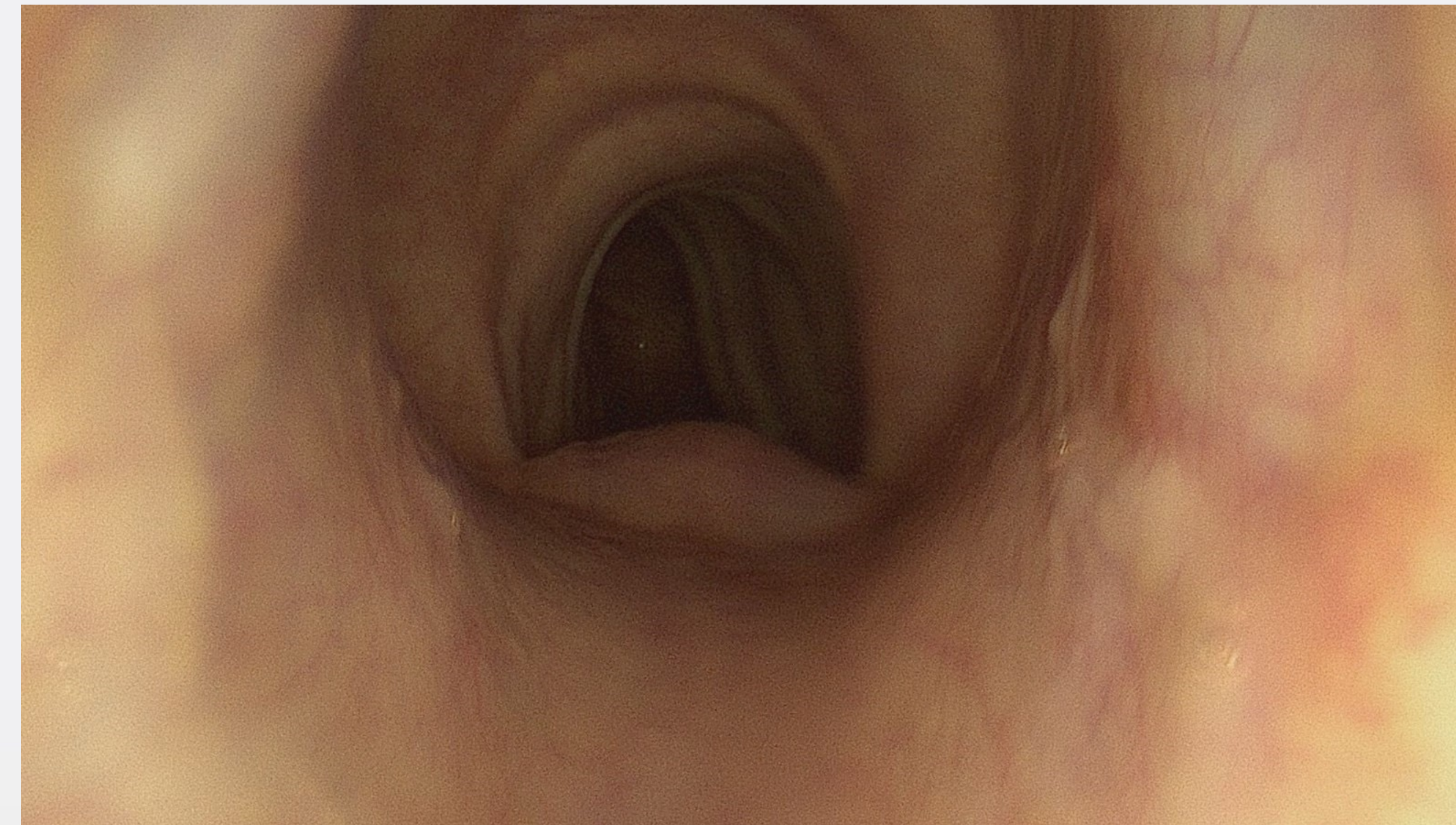


Figure 1: Tracheal expansion during inspiration

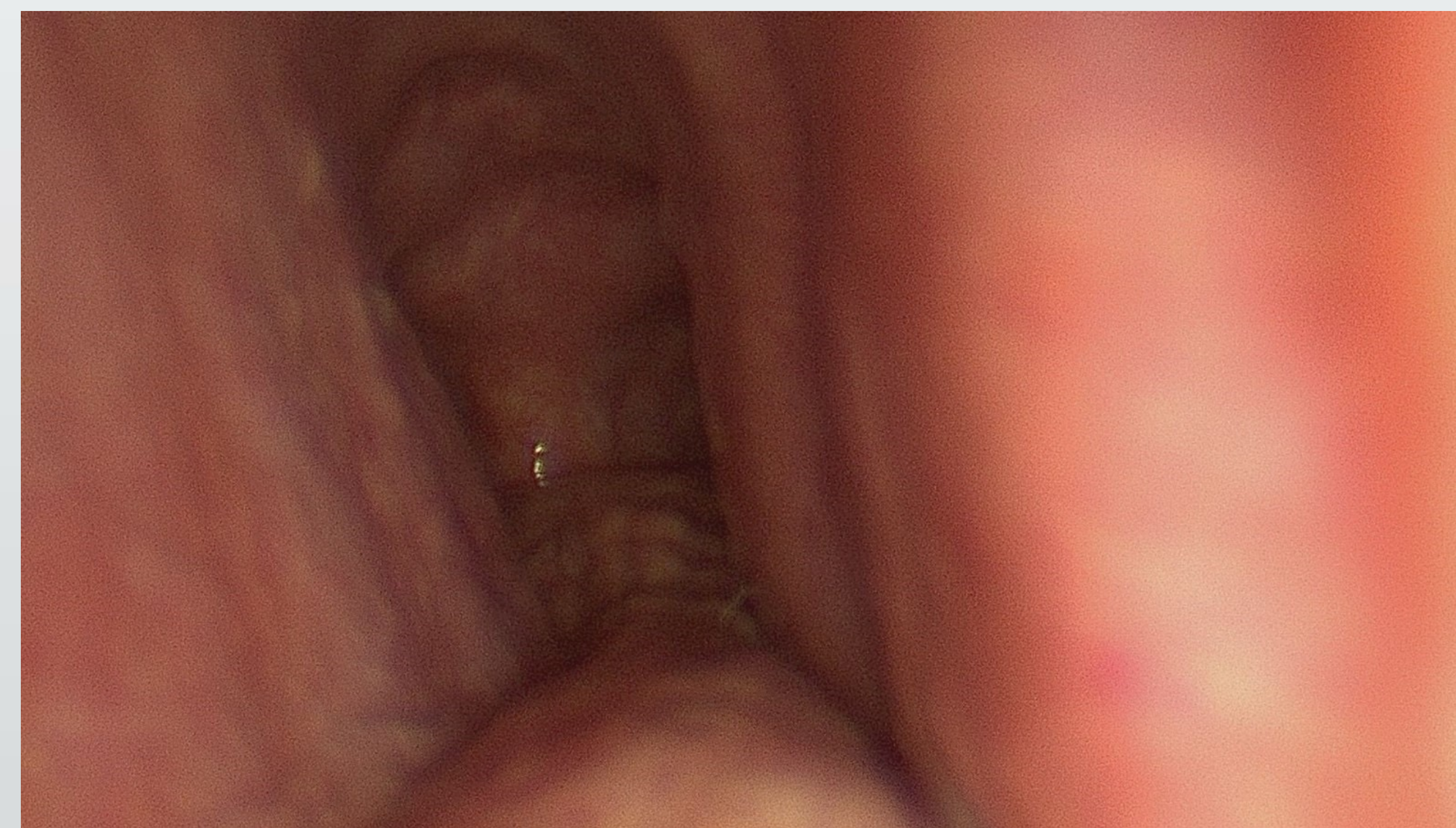


Figure 2: Tracheal collapse and bilateral narrowing during expiration.

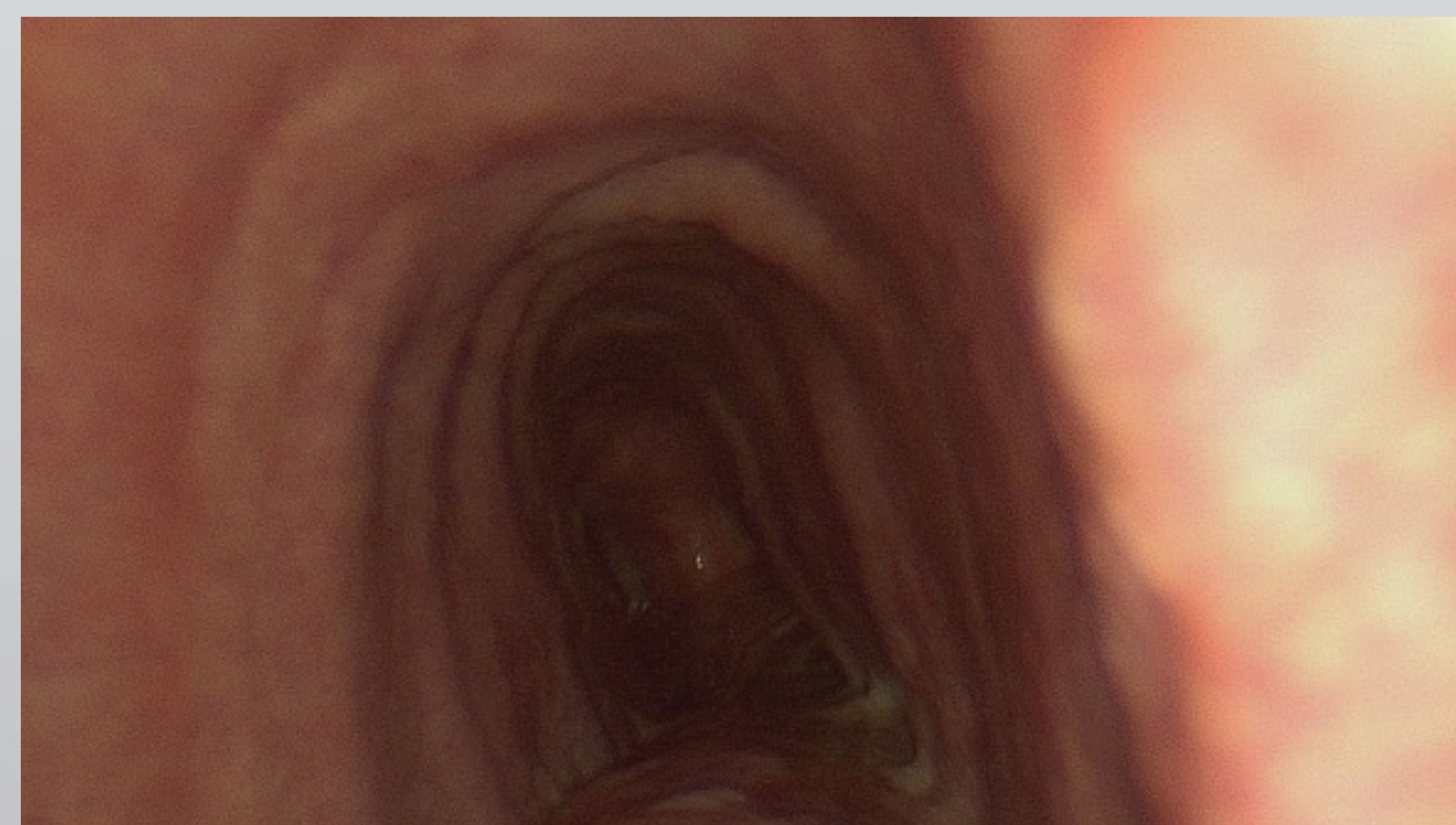

Figure 3: Return to expanded state during inspiration.

PLAN OF CARE

Patient underwent a CT scan of the trachea which showed transverse tracheal narrowing at the level of T3 and tracheal stenosis. He was referred for a diagnostic endoscopy of the larynx and bronchoscopy (figures 1-3).

DISCUSSION

Risk Factors:

- In adults, TM is most often due to an acquired disease process. Tracheostomy or intubation with endotracheal tubes is the most common cause of secondary TM⁵. Traumatic tracheal injury that cause a loss of cartilage, including external trauma and surgery may also cause TM⁶⁻⁸
- Research suggests that chronic inflammation and irritants (ie. cigarette smoke), are the most important contributors to the development of TM^{9,10}. Also, irritation that causes excessive coughing or an increased gag reflex, elevates the intrathoracic pressure and leads to increased collapsibility¹⁰⁻¹¹.

Patient Risk Factors:

- No identifiable factors except cigarette smoke (1/2 pack per day).

Missed Diagnosis:

- A chest AP radiograph is often the first diagnostic test ordered by providers in patients presenting with dyspnea. However, since this abnormality is a dynamic occurrence, chest radiographs often show no abnormalities.
- Often, symptoms of TM closely mirrors that of asthma. Ferraris et al. described patients with acquired TM who reported expiratory dyspnea, the inability to clear secretions, and current respiratory infections – all of which were labeled and treated as asthmatics.

CONCLUSION

- Clinicians should note the nature of dyspnea, constant versus with exertion, and keep TM in their differential diagnosis, especially in men with a positive history of smoking, insignificant pulmonary disease, and gradual, constant symptomatic dyspnea.
- Careful evaluation and monitoring are necessary to determine the best course of management for this rare presentation.

REFERENCES

Please scan the QR code in the top left corner for our references.