

# OFP

Osteopathic Family Physician

THE OFFICIAL PEER-REVIEWED  
PUBLICATION OF THE AMERICAN  
COLLEGE OF OSTEOPATHIC  
FAMILY PHYSICIANS

**MAY/JUNE, 2019**

Volume 11 | Number 3

[ofpjournal.com](http://ofpjournal.com)

## EDITOR'S MESSAGE

Editorial Privileges

## REVIEW ARTICLES

The Value Of Snuffbox Tenderness

An Osteopathic Approach  
To Greater Trochanteric Pain  
Syndrome

Clinical Symptoms Associated  
With Asymptomatic Peripheral  
Arterial Disease

## BRIEF REPORT

Curriculum On Developmental  
Disabilities In Family Medicine  
Residency

## CLINICAL IMAGE

Eyelid Abnormalities In A  
76-Year-Old

## PATIENT EDUCATION HANDOUT

Peripheral Artery Disease



**acofp** | AMERICAN COLLEGE  
OF OSTEOPATHIC  
FAMILY PHYSICIANS

[www.acofp.org](http://www.acofp.org)

## READERS

Osteopathic Family Physician (ISSN 1877-573X) is published bimonthly by the American College of Osteopathic Family Physicians. Periodicals postage paid at Arlington Heights, IL and additional mailing offices.

### USA POSTMASTER

Send address changes to:

American College of Osteopathic Family Physicians  
Membership Department:

330 East Algonquin Rd, Suite 1  
Arlington Heights, IL, 60005  
[membership@acofpca.org](mailto:membership@acofpca.org)

### CUSTOMER SERVICE

(orders, claims, online, change of address)

American College of Osteopathic Family Physicians

330 East Algonquin Rd, Suite 1  
Arlington Heights, IL 60005

800-323-0794 | [membership@acofp.org](mailto:membership@acofp.org)

### YEARLY SUBSCRIPTION RATES

#### United States & Possessions:

Individual \$116 | Institution \$208 | Student \$57

#### All other countries: (prices include airspeed delivery)

Individual \$146 | Institution \$26 | Student \$74  
Single issues \$42

To receive student/resident rate, orders must be accompanied by name of affiliated institution, date of orders must be accompanied by name of affiliated institution, date of term and the signature of program/residency coordinator on institution letterhead. Orders will be billed at the individual rate until proof of status is received. Current prices are in effect for back volumes and back issues.

### ADVERTISING INFORMATION:

Advertising orders and inquiries can be sent to:

**Matt Van Wie**  
804-550-2312 | [matt@esvw.com](mailto:matt@esvw.com)

### AUTHOR INQUIRIES

For inquiries relating to the submission of articles (including electronic submission) please visit [www.ofpjournal.com](http://www.ofpjournal.com).

Content details for questions arising after acceptance of an article, especially those relating to proofs will be provided by the publisher.

You can track accepted articles and view Author Guidelines through Scholar One at [mc04.manuscriptcentral.com/ofp](http://mc04.manuscriptcentral.com/ofp).

## AUTHORS

For a full and complete Guide for Authors, please go to: [mc04.manuscriptcentral.com/ofp](http://mc04.manuscriptcentral.com/ofp).

### REPRINTS:

For queries about author reprints, or to order 100 or more reprints for education, commercial or promotional use, contact ACOFP at 800.323.0794 or email [ashleyd@acofp.org](mailto:ashleyd@acofp.org).

.....  
This journal and the individual contributions contained in it are protected under copyright by ACOFP. The following terms and conditions apply:

### PHOTOCOPYING

Single photocopies of single articles may be made for personal use as allowed by national copyright laws. Permission of the Publisher and payment of a fee is required for all other photocopying, including multiple or systematic copying, copying for advertising or promotional purposes, resale, and all forms of document delivery. Special rates are available for educational institutions that wish to make photocopies for non-profit educational classroom use.

Permission may be sought directly from ACOFP: 800-509-9204 | [membership@acofp.org](mailto:membership@acofp.org).

### DERIVATIVE WORKS

Subscribers may reproduce tables of contents or prepare lists of articles including abstracts for internal circulation within their institutions. Permission of the publisher is required for all other derivative works, including compilations and translations.

### ELECTRONIC STORAGE OR USAGE

Permission of the Publisher is required to store or use electronically any material contained in this journal, including an article or part of an article.

Except as outlined above, no part of this publication may be reproduced, stored in a retrieval system or transmitted in any form or by any means, electronic, mechanical, photocopying, recording or otherwise, without written permission of the Publisher.

Address permission requests to ACOFP at [membership@acofp.org](mailto:membership@acofp.org).

### NOTICE

No responsibility is assumed by ACOFP for any injury and/or damage to persons or property as a matter of products liability, negligence or otherwise, or from any use or operation of any methods, products, instructions or ideas contained in the material herein. Because of rapid advances in the medical sciences, in particular, independent verification of diagnoses and drug doses should be made.

Although all advertising materials is expected to conform to ethical (medical) standards, inclusion in the publication does not constitute a guarantee or endorsement of the quality of value of such product or of the claims made of it by its manufacturer.



# EXAM SCHEDULE

## CERTIFICATION & OCC (RECERTIFICATION)

### EXAMS

#### Family Medicine / OMT

Certification / OCC  
Cognitive Exam

#### Family Medicine / OMT

Certification / OCC  
Performance Evaluation Only

### LOCATIONS

#### Electronic Testing

Regional Sites  
September 28, 2019

#### AOA OMED Conference

Fall, 2019  
exam dates TBD

### POSTMARK DATE

#### April 1, 2019

Late fee through June 1, 2019

#### April 1, 2019

Late fee through June 1, 2019

## ACOFP SEEKS NOMINEES FOR 2020 - 2021 BOARD OF GOVERNORS

ACOFP is now accepting nominations for the positions of *Governor*, *Resident Governor*, and *Student Governor* for the 2020 - 2021 ACOFP Board of Governors. These positions will be elected by the ACOFP Congress of Delegates in March 2020 according to the Nominating Committee process.

**Please visit [acofp.org](http://acofp.org) to submit your nominations by August 15, 2019.**

Address cover letters to:

Annie DeVries, *Executive Assistant/Governance*  
American College of Osteopathic Family Physicians  
330 East Algonquin Road, Suite 1  
Arlington Heights, IL 60005

[annied@acofp.org](mailto:annied@acofp.org)

AMERICAN OSTEOPATHIC BOARD OF FAMILY PHYSICIANS

If you have questions, please call 847.640.8477 or email [aobfp@aobfp.org](mailto:aobfp@aobfp.org).

### BOARD OF GOVERNORS

#### PRESIDENT

Robert C. DeLuca, DO, FACOFP *dist.*

#### PRESIDENT-ELECT

Nicole H. Bixler, DO, FACOFP

#### VICE PRESIDENT

David J. Park, DO, FACOFP

#### SECRETARY/TREASURER

Bruce R. Williams, DO, FACOFP

#### IMMEDIATE PAST PRESIDENT

Duane G. Koehler, DO, FACOFP *dist.*

#### PAST PRESIDENT

Rodney M. Wiseman, DO, FACOFP *dist.*

#### GOVERNORS

Greg D. Cohen, DO, FACOFP *dist.*

David A. Connett, DO, FACOFP *dist.*

Gautam J. Desai, DO, FACOFP

Brian A. Kessler, DO, FACOFP

Saroj Misra, DO, FACOFP

Ronna D. New, DO, FACOFP

#### SPEAKER

Elizabeth A. Palmarozzi, DO, FACOFP

#### VICE SPEAKER

Antonios J. Tsompanidis, DO, FACOFP

#### RESIDENT GOVERNOR

Ryan M. Smith, DO

#### STUDENT GOVERNOR

Athena Chatzigiannidis, OMS III

#### EXECUTIVE DIRECTOR

Bob Moore, MA, CAE

### EDITORIAL COMMITTEE

#### EDITOR

Ronald Januchowski, DO, FACOFP

Associate Dean for Curriculum, VCOM Carolinas Campus, Spartanburg, SC

#### ASSOCIATE EDITOR

Paula Gregory, DO, MBA, CHCQM, FAIHQ

Family Practice, The Villages, Florida

#### MEMBERS

Amy J. Keenum, DO, PharmD, *Chair*

Family & Community Medicine, Michigan State University, East Lansing, MI

David Buford, PhD, OMS III

William Carey University College of Osteopathic Medicine, Hattiesburg, MS

Ryan Christensen, DO

Chief Resident, McLaren-Oakland, Clarkston, MI

Tyler C. Cymet, DO, FACOFP

Chief of Clinical Education, American Association of Colleges of Osteopathic Medicine, Chevy Chase, MD

Robin C. Devine, DO

Assistant Program Director, Grant Family Practice Residency, Columbus, OH

Douglas W. Harley, DO, FACOFP

Associate Program Director, Cleveland Clinic Akron General Family Medicine Residency, Akron, OH

Sara E. Mitchell, DO

Family Medicine, HealthEast Care System, St Paul, MN

Jon S. Parham, DO

Program Director/Director of Med Ed, LMU-DeBusk - The University of Tennessee Graduate School of Medicine, TN

Wayne J. Reynolds, DO

Family Medicine, Sentara Medical Group, Gloucester, VA

Lindsay Saleski, DO, MBA, FACOEP

Emergency Department, Palmetto Health Tuomey, Sumter, SC

Abraham Wheeler

Librarian, Michigan State Libraries, East Lansing, MI

#### EMERITUS MEMBER

Merideth Norris, DO, FACOFP

Grateful Recovery, Kennebunk, ME

#### WRITING MENTOR

Jay H. Shubrook, Jr., DO, FACOFP

Professor, Touro University College of Osteopathic Medicine, Vallejo, CA

#### DEPARTMENT CHAIR

Saroj Misra, DO, FACOFP

Ascension Macomb-Oakland Hospital, Rochester Hills, MI

#### STAFF LIAISONS

Belinda Bombei & Samantha Grycowski

ACOFP, Arlington Heights, IL

### EDITOR'S MESSAGE

#### Editorial Privileges

*Ronald Januchowski, DO, FACOFP, Editor*

### FROM THE PRESIDENT'S DESK

#### Keeping Osteopathic Focus for the ACOFP Family

*Robert C. DeLuca, DO, FACOFP dist.*

### LETTER TO THE EDITOR AND RESPONSE

#### Pelvic Venous Congestion Syndrome

### REVIEW ARTICLES

#### The Value Of Snuffbox Tenderness: A Sign Of Things To Come

*Shawn Warner, DO, PGY-1; Eric Mast, DO; James Berry, MD; Dave Pocos, DO*

#### An Osteopathic Approach To Greater Trochanteric Pain Syndrome

*Jonathan W. Torres, DO ; Christopher Zipp, DO, FACOFP*

#### Clinical Symptoms Associated With Asymptomatic Peripheral Arterial Disease: A Literature Review

*Arthur Tarricone, MPH; Ruben Dovlatyan, OMS I; Karla De La Mata, BS; Joseph S. Coppola, BS; Prakash Krishnan, MD, FACC*

### BRIEF REPORT

#### Curriculum On Developmental Disabilities In Family Medicine Residency

*Bernadette Riley, DO, FACOFP, FILM*

### CLINICAL IMAGE

#### Eyelid Abnormalities In A 76-Year-Old Male

*Leonid Skorin, Jr., DO, OD, MS; Marisa Asheim, BS*

### CALENDAR OF EVENTS

#### 2019 Calendar of Events

### PATIENT EDUCATION HANDOUT

#### Peripheral Artery Disease: Know Your Risk Factors

7

8-9

10

12-17

18-21

22-29

30-33

34-37

38

42



## OSTEOPATHIC FAMILY PHYSICIAN SPECIALTY PEER REVIEWERS

---

**Nazem Abdelfatta, MD**  
Family Medicine, Obstetrics, Women's Health

**Richard L. Averitte, Jr, MD**  
Dermatology

**Jeffrey Benseler, DO**  
Radiology

**Shagun Bindlish, MD**  
Diabetes and Endocrinology

**Warren Bodine, DO**  
Sports Medicine & Family Medicine

**Grace Brannan, PhD**  
Statistics/Design

**Natasha Bray, DO**  
Ethics

**Omar Bukhari, DO**  
Family Medicine, Obstetrics

**Janis Coffin, DO**  
Practice Management

**Philip Collins, DO**  
Patient Education

**Danielle Cooley, DO**  
OMM

**Andrew Crow, DO**  
Academic, Emergency, Hospital Care, Military

**Rob Danoff, DO**  
Emergency Medicine, Preventive

**Robin Devine, DO**  
Statistics/Design

**Brian Downs, DO**  
HIV, Wound Care

**Dennis Eckles, DO**  
Diabetes, Rural Medicine

**Gail Feinberg, DO, FCOFP**  
Academic

**Patricia Happel, DO**  
Nutrition and Obesity

**Robert Hunter, DO**  
Health Policy, Hospice/Palliative Care,  
ER, Diabetes, Wound Care

**Ronald P. Januchowski, DO**  
Military & Rural/Underserved

**Steve Kamajian, DO, CMD, FCOFP**  
Family Medicine, Geriatrics, Long Term Care

**Amy Keenum, DO, PharmD**  
Healthy Literacy, International & Patient Education

**Uzma Khan, DO**  
Family Medicine

**Frank Komara, DO**  
Geriatrics

**Mana Lazzaroto, DO**  
Clinical Images

**Ehab Mady, DO**  
Vascular

**Mohammad Mansour, MD**  
Inpatient Medicine, Cardiology, Pulmonary,  
Geriatrics, Obstetrics

**Marjan Moghaddam, DO**  
Family Medicine

**Merideth Norris, DO, FCOFP**  
Addiction

**Jon Parham, DO**  
Preventive Medicine, Pulmonary, Public Health,  
Geriatrics, Medical Errors

**Raena Pettitt, DO**  
Disease Prevention & Wellness

**Kim Pfothenauer, DO**  
Diabetes

**Prabhat Pokhrel, MD, MS, PhD, FAAFP**  
Pharmacology, Cardiology,  
Nephrology, Pulmonology

**M. Jay Porcelli, DO, FCOFP *dist.***  
Pain Management

**Jill Yurko Porter, DO**  
Obesity, OMT, Physician Wellness  
and Women's Health

**Joseph Reyes, DO**  
Pain Management

**Bernadette Riley, DO**  
Medical Education, Academic, Simulation  
Medicine, Physician Leadership, Health Policy

**Mark Rogers, DO, MA, CAQSM, FAAFP**  
Family Medicine, Sports Medicine, OMM,  
Medical Ethics

**Kary Schroyer, DO**  
Direct Primary Care

**Christopher Scuderi, DO**  
Family Practice, Practice Management

**Jay Shubrook, Jr., DO, FCOFP**  
Endocrinology

**Leslie Sleuwen, MD**  
Community Medicine

**Frederick Stine, DO**  
Pediatrics, Nephrology, Emergency & Critical Care

**Lindsay Tjiattas-Saleski, DO**  
Clinical Images, Emergency Medicine

**Johnathon Torres, DO**  
OMM

**Chad Uptigrove, DO**  
Obstetrics, Residency Training

**Michael Watkins, DO**  
OB/GYN & Women's Health

**Barbara Wolf, DO**  
Psychology

**William Woolery, DO, PhD, FCOFP**  
Geriatrics

**Julian Vega, DO**  
Clinical Images

**Sheldon Yao, DO**  
Cardiology

**Nicholas Pennings, DO, FOMA**  
Obesity

## 2019 STUDENT ACADEMIC & PEER REVIEW WRITING INTERNS

---

**Michael Anderson**  
William Carey University College of Osteopathic Medicine

**Steven Bean**  
William Carey University College of Osteopathic Medicine

**Alex Belote**  
William Carey University College of Osteopathic Medicine

**Anmol Bhatia**  
A.T. Still University - School of Osteopathic Medicine in Arizona

**Lindsay Bigham**  
William Carey University College of Osteopathic Medicine

**Shelbi Bolton**  
William Carey University College of Osteopathic Medicine

**Johnny Campbell Jr.**  
William Carey University College of Osteopathic Medicine

**Tessa Cucurullo**  
William Carey University College of Osteopathic Medicine

**Alice Doong**  
Michigan State University College of Osteopathic Medicine

**Angelic Dye**  
William Carey University College of Osteopathic Medicine

**Zachary D. Ellis**  
William Carey University College of Osteopathic Medicine

**Kimia Etemadi**  
A.T. Still University - School of Osteopathic Medicine in Arizona

**Joanna Gobrial**  
A.T. Still University - School of Osteopathic Medicine in Arizona

**Kathryn Johnson**  
A.T. Still University - School of Osteopathic Medicine in Arizona

**Chris Koerber**  
A.T. Still University - School of Osteopathic Medicine in Arizona

**Nadia Khan**  
Michigan State University College of Osteopathic Medicine

**Matthew Kon**  
William Carey University College of Osteopathic Medicine

**Liana Kobayashi**  
A.T. Still University - School of Osteopathic Medicine in Arizona

**Luiza Mnatsakanyan**  
William Carey University College of Osteopathic Medicine

**Amelia Ni**  
A.T. Still University - School of Osteopathic Medicine in Arizona

**Abi Moeller**  
A.T. Still University - School of Osteopathic Medicine in Arizona

**Hennah Patel**  
William Carey University College of Osteopathic Medicine

**Amena Payami**  
William Carey University College of Osteopathic Medicine

**Elenie Phillippas**  
Western University of Health Sciences College of  
Osteopathic Medicine of the Pacific

**Mike Ramalia**  
Michigan State University College of Osteopathic Medicine

**Shivani Reddy**  
William Carey University College of Osteopathic Medicine

**Syed Danyal Raza**  
William Carey University College of Osteopathic Medicine

**Diana Roy**  
William Carey University College of Osteopathic Medicine

**Aryan Sharif**  
A.T. Still University - School of Osteopathic Medicine in Arizona

**Sara Shu**  
Western University of Health Sciences College of  
Osteopathic Medicine of the Pacific

**Jordan Burr**  
A.T. Still University - School of Osteopathic Medicine in Arizona

**Nicholas S. Tito**  
William Carey University College of Osteopathic Medicine

**Elysia Tjong**  
A.T. Still University - School of Osteopathic Medicine in Arizona

**Nusrat Uddin**  
William Carey University College of Osteopathic Medicine

## 2019 CALL FOR PAPERS

Osteopathic Family Physician is the ACOFP's official peer-reviewed journal. The bi-monthly publication features original research, clinical images and articles about preventive medicine, managed care, osteopathic principles and practices, pain management, public health, medical education and practice management.

### RESERVE A TOPIC

Reserve a review article topic today by emailing ACOFP Managing Editor, Belinda Bombei at [belindab@acofp.org](mailto:belindab@acofp.org). Please provide your name and the review title you would like to reserve. Once you reserve a review article topic, you will receive an email confirmation from ACOFP. This will initiate a three-month deadline for submission. If the paper is not received within three months, the system will release the review article topic for other authors to reserve. Articles submitted for publication must be original in nature and may not be published in any other periodical. Materials for publication should be of clinical or didactic interest to osteopathic family physicians. Any reference to statistics and/or studies must be footnoted. Material by another author must be in quotations and receive appropriate attribution. ACOFP reserves the right to edit all submissions. Visit [ofjournal.com](http://ofjournal.com) to view author guidelines, policies, and manuscript checklist.

### CLINICAL IMAGES

We are seeking clinical images from the wards that covers essential concepts or subject matter to the primary care physician. Please provide a brief synopsis of how the case presented along with 1-4 questions and approximately 1 page of education with reference to the image and questions.

### REVIEW ARTICLE TOPICS

- Disorders of Puberty: An Approach to Diagnosis and Management with an osteopathic component
- Chronic Kidney Disease: Detection and Evaluation with an osteopathic component
- Direct Primary Care: Emerging Practice Alternative with an osteopathic component
- Diagnosis and Management of Non-Melanoma Skin Cancer with an osteopathic component
- OMT treatments for pediatric conditions: a systematic review
- Non-Allergic Rhinitis with osteopathic component

### RESEARCH TOPICS

We are seeking original clinical or applied research papers. Original contributions include controlled trials, observational studies, diagnostic test studies, cost-effectiveness studies, and survey-based studies. The OFP will accept basic scientific research only if the work has clear clinical applications. For randomized controlled trials, study flow diagrams must be submitted. For all other types of original contributions, flow diagrams are encouraged. Original contributions should be 3000 words with no more than 50 references and 5 tables or figures. OFP requires you to submit a 250-word abstract, along with four to six keywords.

The content should include the following:

Abstract	Discussion
Introduction	Conclusions
Methods	Acknowledgments
Results	

# EDITOR'S MESSAGE

## Editorial Privileges

Ronald Januchowski, DO, FACOFP, Editor, *Osteopathic Family Physician*

Welcome to another issue of *Osteopathic Family Physician*.

Caution, dad joke ahead. "April showers bring May flowers. What do May flowers bring?"


As the Editor-in-Chief of OFP I get to work with some incredible people to assemble this premier journal for our profession. From the Managing Editor to the Editorial committee members and contributing authors, all are dedicated to producing a great resource and reference for clinical practice.

I had the privilege last month to speak with a number of potential contributors to OFP at the Family Medicine Program Directors' meeting. I presented to a group of medical educators working with what will hopefully be the next motivated set of primary care physician authors. A big thanks to Dr. Rob Danoff for allowing this to happen. I hope to see future submissions from this group and look forward to working to help this group of educators meet their scholarly activity requirements. As OFP moves forward this year towards full Medline listing, I anticipate the quantity and quality of articles to far surpass previous years!

Besides providing primary care updates and reviews, one of the unique features of *Osteopathic Family Physician* is the inclusion of Osteopathic specific examination, treatment, or management options for our patients. I enjoyed reviewing Dr. Torres' article in this issue on greater trochanteric pain syndrome. Imaging is nice, but having a good hands-on examination is critical for efficient and cost-effective care for our patients. More examination skills are highlighted in the article on snuffbox tenderness. Creating an atmosphere of mind-body-spirit is stressed in Dr. Riley's article on a novel curriculum for Family Medicine residents. Another privilege of being Editor-in-Chief is seeing the submissions become part of the medical literature helping family medicine D.O.'s become better doctors. Being an excellent Osteopathic Family Physician means more than just doing OMT!

End of dad joke: "Pilgrims."

Have a wonderful next couple of months and we will see you in the summer!



## FROM THE PRESIDENT'S DESK



### Keeping Osteopathic Focus for the ACOFP Family

Robert C. DeLuca, DO, FACOFP *dist.*

2019 - 2020 ACOFP President

The 2019 ACOFP Annual Convention was the culmination of a great year for osteopathic family medicine. Through the leadership of Dr. Duane Koehler this past year, our profession has a very bright and exciting future. The ACOFP Board and I, as the 2019-2020 President, will continue with programs that will focus on "keeping osteopathic family medicine osteopathic."

#### LEADERSHIP

Over the next year, we will look for new ways to engage members, better communicate, and improve perceptions of osteopathic training and certification.

Last year we conducted a communication audit to identify new ways to tell our story. The staff team remains committed to trying new things, including increasing our social media presence. We are making new connections, creating more videos and educational content, posting to LinkedIn, and have started an Instagram account that was quite popular at the Convention.

Another way we're looking to increase engagement is through our volunteer opportunities. To make for more meaningful volunteer experiences and successful results of each committee, the ACOFP Board reviewed and approved updated committee charges and goals for the coming year. We are taking a closer look at how each committee functions this year to determine if we are achieving our goals. If goals have not been reached, there may be other ways we can engage with members.

As one means to help increase member engagement, we formed a few new committees.

- First, we have created a **Knowledge, Learning & Assessment Advisory Committee**. The goal of this group is to convene the chairs of committees that produce content, programs and services. There is an opportunity to better connect these groups to maximize efforts in a strategic way.

- A **Residency Program Directors Committee** was established to maintain and advance the process of osteopathically-focused graduate medical education and increase the number of programs that enhance in this process.

- The **Family Medicine Chairs Committee** was created to work with the US-based Colleges of Osteopathic Medicine Family Medicine/Primary Care departments to encourage osteopathic medical students to consider family medicine as a career, to encourage students to choose osteopathic recognized residency programs and to foster the osteopathic spirit and solidarity. Also, this group will help strengthen ties between COMs/Family Medicine Residency Programs with Osteopathic Recognition and the ACOFP by promoting the unique characteristics of Osteopathic Principles and Practices.

- Last, but not least, the **Preceptorship Committee** has been charged with identifying and educating high-quality preceptors to promote excellence and innovation with third and fourth-year osteopathic medical students to enhance their interest in osteopathic family medicine.

#### EDUCATION

ACOFP's education goal is to be the leading source of osteopathic post graduate instruction in the country. At the Residency Directors workshop during ACOFP '19, there was a great surge of excitement when the AOBFP, AOA and the ACOFP jointly announced the initial phase of changes in the certification process. This culminated many years of work by these groups to streamline both initial and re-certification process.

We will continue our efforts to keep the dialog open with AOBFP and AOA to ensure that initial certification and OCC evolve in a way that maintains their high quality, osteopathic focus, but is flexible, more cost-effective and reflective of today's learning style preferences.

We are excited about a new program for residents: Early Entry into OCC During Residency Training. A resident enrolled in an ACGME Family Medicine residency may be provisionally enrolled in OCC prior to completion of training by meeting certain requirements. Residents must complete two of three yearly AOBFP InService Exams during their residence, and pass the AOBFP Early Entry Initial Certification (EEIC) cognitive exam during year three of residency. Upon satisfying these requirements and verification of

residency completion status, certification will be granted and the individual will be officially enrolled in OCC.

#### ADVOCACY

As part of our Federal & State Legislation Committee, the "Act Now" subcommittee is being formed to engage with new professionals and others interested in supporting Direct Primary Care legislation and resources. Also, they will work to support legislation in favor of physician-led health care teams opposing unsupervised practice of medicine by other health professionals.

ACOFP not only advocates for members with government agencies but also within the medical profession and affiliates. The ACOFP Congress of Delegates passed several important resolutions that will be forwarded to the AOA House of Delegates in support of cooperation between the ACOFP, AOBFP and the

AOA regarding the continued focus on the osteopathic component of our education and evaluation programs.

As you can see, ACOFP has several new and exciting initiatives in the pipeline. This summer the Board will strategize a viable and visible pathway forward for our profession. Our goal is to not only keep pace with change and support the osteopathic agenda but to proactively exert ourselves as the leaders for our specialty and the professional home for osteopathic family physicians.

Robert C. DeLuca, DO, FACOFP *dist.*

2019 - 2020 ACOFP President

### Rocky Mountain OPTI/Sky Ridge Medical Center Neuromusculoskeletal Medicine + 1 Residency

Our program was established to enable physicians who have already completed a residency in an approved specialty to spend an extra year enhancing their skills in neuromusculoskeletal medicine and osteopathic manipulative medicine (NMM/OMM). Our goal is to develop highly trained physicians who can act as both clinicians and academicians. Our program places a significant emphasis on the integration of osteopathic manipulative medicine and the principles of primary care sports medicine. Our residents develop their Osteopathic clinical skills by providing inpatient care at Sky Ridge Medical Center and outpatient care at the Rocky Vista Health Center and other associated outpatient clinics.

Our program also includes such rotation choices as neurological surgery, occupational medicine, orthopedic spine surgery, podiatric medicine, primary care sports medicine, neurology, physical medicine and rehabilitation, rheumatology, musculoskeletal radiology, medical acupuncture, family medicine, integrative medicine, functional medicine, hospice and palliative care, internal medicine, obstetrics and gynecology and pediatrics. Academic development occurs through the Rocky Vista University College of Osteopathic Medicine in Parker, Colorado. Successful program completion will allow the physician to apply for the Neuromusculoskeletal Medicine/Osteopathic Manipulative Medicine certification examination.

**Kenneth A. Ramey, DO, FACOFP serves as the program director and is a 1994 graduate of the Chicago College of Osteopathic Medicine. He is board certified in family medicine/osteopathic manipulative treatment, neuromusculoskeletal medicine/osteopathic manipulative medicine and has a certificate of added qualification in sports medicine. Dr. Ramey is a member of the medical staff at Sky Ridge Medical Center and has served as a team physician at the high school, college and semi-professional levels. He is an Associate Professor of OPP at Rocky Vista University and serves as the Director of the Sports Medicine and Osteopathic Manipulative Medicine Program at the Rocky Vista Health Center.**

We have received ACGME Pre-Accreditation and would be honored to consider your application for our program. Please send a current CV, letter of interest and three letters of recommendation (including one from your residency director) to Dr. Ramey at [kramey@rvu.edu](mailto:kramey@rvu.edu). Please call Dr. Ramey at (720) 874-2421 if you need additional information.

"The purpose of Osteopathy is to make life a little more comfortable for the patient."

"What are the limits of Osteopathy? No one knows the limits of Osteopathy."

John Martin Littlejohn, DO



## LETTER TO THE EDITOR

## Reminder the PVCS is a Part of the Differential for Pelvic Pain

To the Editor:

The recent article “*Chronic Abdominal Pain: Tips for the Primary Care Provider*” (January/February 2019) provided an excellent overview of the topic. However, I want to remind my colleagues that *Pelvic Venous Congestion Syndrome* is also part of the differential for pelvic pain.

*Pelvic Venous Congestion* (PVCS) is the process of valve failure of veins or organs in the pelvis, similar to varicose veins in the legs. Those internal varicose veins can cause symptoms similar to those described in the article. Patients will often have visible varicose veins on their upper legs or, sometimes, the labia. The main symptom is pelvic pain that lasts for six months or more. Patients with PVCS report a prolonged deep and dull ache, often associated with movement, posture, and activities that increase abdominal pressure. Like varicose veins in the leg, the achiness that increases with prolonged standing can often be relieved by lying flat or elevating the legs.

PVCS usually affects women who have previously been pregnant, because the ovarian and pelvic veins widened during pregnancy to accommodate the increased blood flow from the uterus. After the pregnancy, some of these veins remain enlarged, causing them to weaken and allow blood to pool or flow in the wrong direction. Similar to varicose veins in the legs, venous congestion in the pelvis often first manifests during or after a pregnancy and worsens with subsequent pregnancies.

Risk factors for PVCS may include a family history of the condition, hormonal influence, pelvic surgery, multiple pregnancies, a retroverted uterus, and a history of varicose veins. African American women and women over 35 years of age have a lower risk of developing this condition.

After an initial exam, a number of non- or minimally-invasive diagnostic tests can be performed to determine whether chronic pelvic pain is a result of pelvic varicose veins. These tests include pelvic ultrasound, pelvic venography, Computed Tomography, and Magnetic Resonance Imaging. For patients with PVCS, interventional radiologists are a critical part of their care team.

There are a number of treatments for those diagnosed with pelvic venous congestion syndrome: medical, surgical, and minimally invasive. According to clinical practice guidelines by the *Society for Vascular Surgery* and the *American Venous Forum*, embolization of refluxing ovarian veins with coils, plugs, or sclerotherapy (usually in combination), has become the standard approach for management of PVCS.

With regard to the “*Chronic Abdominal Pain*” article, I suggest adding a vascular section to *Table 2*, which lists other possible systems. Additionally, *Figure 1* does allude to vascular, though it only reflects arterial dysfunction.

Cindy Asbjornsen, DO, FACPh

Founder, Vein Healthcare Center  
South Portland, Maine  
www.veinhealthcare.com

## Response

Dear Dr. Asbjornsen,

We appreciate your feedback to our manuscript, “*Chronic Abdominal Pain: Tips for the Primary Care Provider*.” The prevalence of PCVS is 15% in females aged 18 to 50 years in the United States and up to 43.4% worldwide. While this should be listed under pelvic pain, it is not high on the differential diagnosis for chronic abdominal pain. In addition, we have acknowledged your suggestion of adding a vascular section to *Table 2*.

Thank you for your feedback.

Kind regards,  
Dr. Gina Charles



ACOF 57<sup>th</sup> Annual Convention & Scientific Seminars

acofp '20

MARCH 19 - 22, 2020

Over 30 Category 1-A CME Credits anticipated!

Register online this fall at [www.acofp.org](http://www.acofp.org).



## REVIEW ARTICLE

# The Value of Snuffbox Tenderness: A Sign of Things to Come

Shawn Warner, DO, PGY-1<sup>1</sup>; Eric Mast, DO<sup>2</sup>; James Berry, MD<sup>2</sup>; Dave Pocos, DO<sup>3</sup>

<sup>1</sup>Firelands Regional Medical Center, Sandusky, OH

<sup>2</sup>Firelands Physician Group, Sandusky, OH

<sup>3</sup>NOMS Access Orthopedics, Norwalk, OH

## KEYWORDS:

Avascular Necrosis

Malunion

Nonunion

Orthopedics

Scaphoid Fracture

Snuffbox Tenderness

**ABSTRACT:** The scaphoid is the most commonly fractured bone within the carpal bones, accounting for up to 70% of all carpal fractures and frequently occurs following a fall onto an outstretched hand. Despite the high frequency of injury and a common mechanism of injury, it is common for a scaphoid fracture to go undiagnosed. In this setting, the patient is now at risk for numerous long-term complications. Using a case report of a 30-year-old male who had improper management of an acute scaphoid fracture, this article will review the proper management in the acute setting with advanced imaging and briefly discuss the long-term complications of an improperly treated fracture.

## HISTORY, PHYSICAL EXAM, AND DIAGNOSTIC ASSESSMENT

A 21-year-old male presented to the Emergency Department (ED) complaining of increasing left wrist pain at the base of the thumb. He states that he crashed his All-Terrain Vehicle (ATV) during a motocross race one day prior, subsequently landing on his stomach with his hands outstretched in front of him. The physical exam was positive for snuffbox tenderness while the wrist is in ulnar deviation. Plain film radiographs were taken of his left wrist (*Figure 1*). No fracture was reported, and he was discharged from the ED with a diagnosis of a left wrist sprain, immobilized in a removable thumb spica splint, and instructed to follow up with his primary care physician (PCP) in two weeks.

On follow up with PCP the patient's wrist pain was still present and the physical exam remained positive for snuffbox tenderness. He was then instructed to continue wearing the thumb spica splint and return in two weeks if the pain persisted. The patient returned to his PCP reporting no improvement of symptoms,

and a technetium-99 scan was ordered (*Figure 2*). The technetium scan read positive for evidence of bone pathology in the left wrist, and at this time was placed in a short arm cast and instructed to follow up in four weeks. On return visit, he reported no improvement of symptoms and was subsequently referred to an orthopedic surgeon. At the initial visit with the surgeon, plain film radiographs of the left wrist were ordered and showed evidence of fracture of the left scaphoid (*Figure 3*).

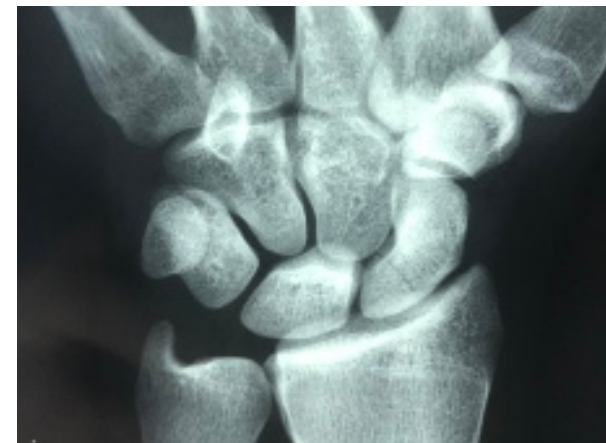At that point, he was then referred to a hand and wrist specialist for further management. After reviewing the case, it was decided to continue with nonoperative management and he was placed in a short arm cast with daily bone stimulator treatments. The patient continued to follow up with the hand specialist for repeat imaging every month to assess the status of the fracture. At month nine the fracture was labeled nonunion, and the surgeon recommended no further treatment and the patient was subsequently removed from the cast and told to return to activity as tolerated with no further follow up visits scheduled. Unfortunately, images from the hand and wrist specialist were not available.

## CORRESPONDENCE:

Shawn Warner, DO, PGY-1 | [sw732913@ohio.edu](mailto:sw732913@ohio.edu)

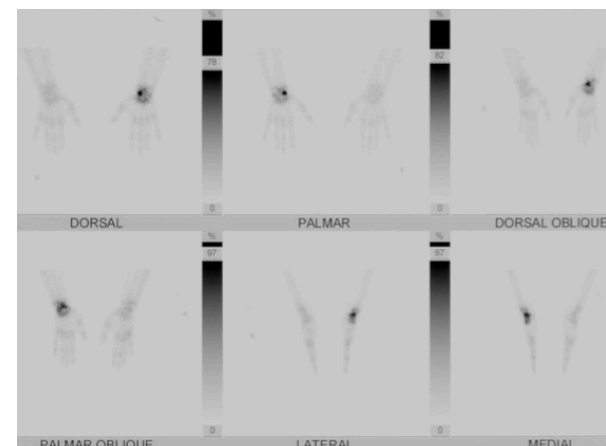
**FIGURE 1:**

Plain film radiographs - left wrist



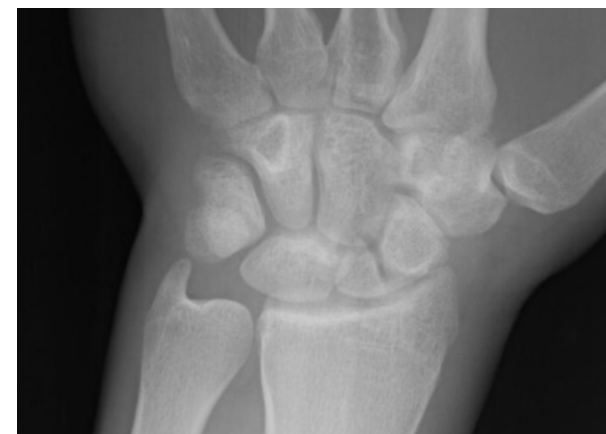**FIGURE 2:**

Technetium-99 Scan



**FIGURE 3:**

Plain film radiographs - evidence fracture left scaphoid



## INTRODUCTION

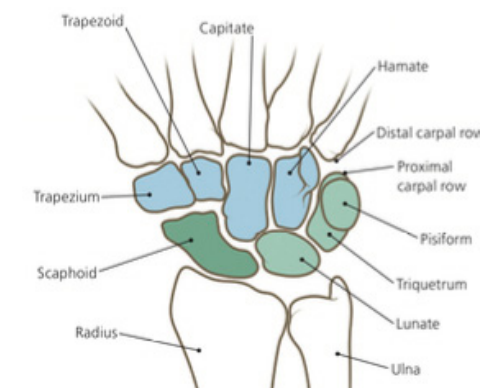
Carpal fractures comprise approximately 18% of all hand fractures.<sup>1</sup> When considering fractures within the carpal bones, the scaphoid is the most commonly affected, accounting for 60-70% of all carpal fractures.<sup>1</sup> Despite being the most commonly fractured carpal bone with a telltale mechanism of injury, a fracture of the scaphoid bone can be a difficult diagnosis to make. This is likely due to an array of nonspecific symptoms and a lack of evidence of a fracture on initial plain film radiographs.<sup>2</sup> Due to the nature of the scaphoid structure, function, and its blood supply, there is an increased likelihood that trauma to the scaphoid can lead to long term complications. If a scaphoid fracture is suspected but the plain film radiographs are negative, it warrants further investigation in a timely manner.

## ANATOMY

As depicted by its name, the scaphoid has a curved or "boat" shape to it. The scaphoid itself rests in a concave groove within the distal radius where it articulates with the radius and four carpals; the lunate, trapezium, trapezoid, and capitate<sup>1</sup> (*Figure 4*). Due to its extensive articulation and small size, roughly 82% of the bone is covered in articular cartilage, leaving limited access for its arterial supply.<sup>3</sup> Due to a study performed in 1980 by Gelberman et al, it has classically been taught that the primary blood supply for the scaphoid was supplied by the radial artery via a dorsal and volar branch, which enter through a bony foramina located at either the waist or the distal aspect in 93% of people.<sup>4</sup> This study showed that the two arteries that enter at the dorsal ridge supplied 70-80% of the proximal scaphoid via intraosseous retrograde flow and the distal 20-30% was supplied by branches surrounding the tubercle.<sup>4,5</sup> However, more recently it has been shown using cadavers that the scaphoid blood supply is more extensive than previously thought.<sup>3,5</sup> In some of the cadavers, the proximal, middle, and distal third of the scaphoid all may receive a direct blood supply. Although there is some anatomical variance described between the cadavers as far as the presence or absence and the size of the vessels, the surrounding arteries are able to compensate if one branch is completely missing.<sup>3</sup>

**FIGURE 4:**

Anatomy of the scaphoid

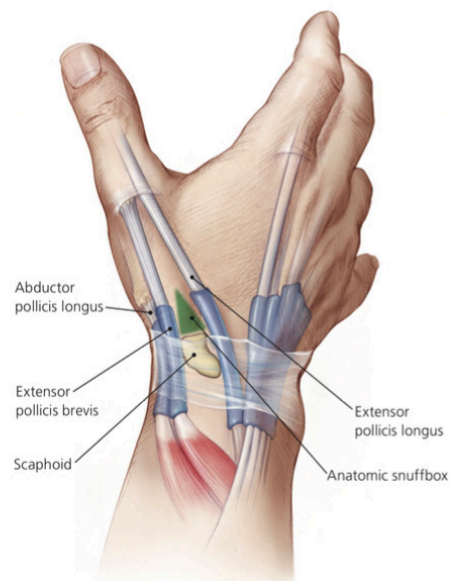


©Scott Bodell. Used with permission.



FIGURE 5:

Trapezium and scaphoid – forming snuffbox floor



©Christy Krames. Used with permission.

The scaphoid can be palpated in three locations within the wrist. The tubercle of the scaphoid is the most prominent feature of the scaphoid and can be palpated on the palmar aspect of the wrist while it is in ulnar deviation. The remaining two locations are within the anatomic snuffbox and on the dorsal aspect of the wrist approximately in the same location as the scaphoid tubercle. The anatomic snuffbox is located on the radial aspect of the wrist at the level of the carpals. It is defined by the extensor pollicis longus (EPL) tendon medially, the extensor pollicis brevis (EPB) and abductor pollicis longus (APL) tendons laterally, the proximal border is the radial styloid process, and the distal border is the approximation of the EPL, EPB, and APL tendons. The floor of the snuffbox is formed by the trapezium and the scaphoid (Figure 5).

### MECHANISM OF INJURY

The most common mechanism of injury in a scaphoid injury is a fall onto an outstretched hand or a direct axial load.<sup>1</sup> A fall onto an outstretched hand imposes a forceful combination of wrist dorsiflexion usually exceeding 95 degrees, ulnar deviation, and intercarpal supination. With this motion, the midbody, or “waist,” of the scaphoid that articulates with the distal radius is then forced against the dorsal lip of the radius, causing injury.<sup>1</sup>

### PHYSICAL EXAM

In the acute setting, a patient will typically present reporting an injury related to either of the two mechanisms previously mentioned with pain and swelling over the radial aspect of the wrist.

While performing a physical exam on a patient with a possible scaphoid injury, there are a few special tests that should be performed in addition to the standard orthopedic assessment of an injured wrist. The first of which is palpation of the anatomic snuffbox (Figure 6). As previously mentioned, the floor of the snuffbox consists of the scaphoid, and pain with direct palpation is indicative of a scaphoid fracture and should be treated as such until proven otherwise.<sup>6</sup> Snuffbox tenderness has a sensitivity of 86% and a specificity of 30%.<sup>7</sup> Another physical exam test is known as scaphoid tubercle tenderness. This requires the examiner to locate the scaphoid tubercle on the volar aspect of the wrist and apply direct pressure.<sup>6</sup> As the name implies, if there is tenderness with direct pressure, this is considered a positive test and points towards a scaphoid injury (Figure 7). Scaphoid tubercle tenderness has a sensitivity of 95% and a specificity of 74%.<sup>7</sup> The Watson shift test is another physical exam maneuver designed to identify a scaphoid injury. The patient must sit with their elbow resting on the table and forearm pronated. With one hand, the examiner must slightly extend the wrist and then place it in ulnar deviation. With the other hand, the examiner must apply pressure to the volar aspect of the scaphoid with the thumb and place the fingers on the dorsal aspect of the wrist to provide counter pressure (Figure 8). The examiner should then radially deviate and slightly flex the patient's wrist. If there is instability of the scaphoid due to a fracture or ligamentous disruption, the dorsal pole of the scaphoid will sublux or “shift” over the dorsal rim of the radius, reproducing pain. If there is only pain on this maneuver, it is indicative for a scaphoid fracture, but if the “shift” is felt, this may also point towards damage to the scapholunate ligament.<sup>6</sup> The Watson shift test has a sensitivity of 43% and a specificity of 30%, which are relatively low, but the test can still be useful when the diagnosis is not clear.<sup>7</sup>

FIGURE 6:

Palpation of the anatomic snuffbox

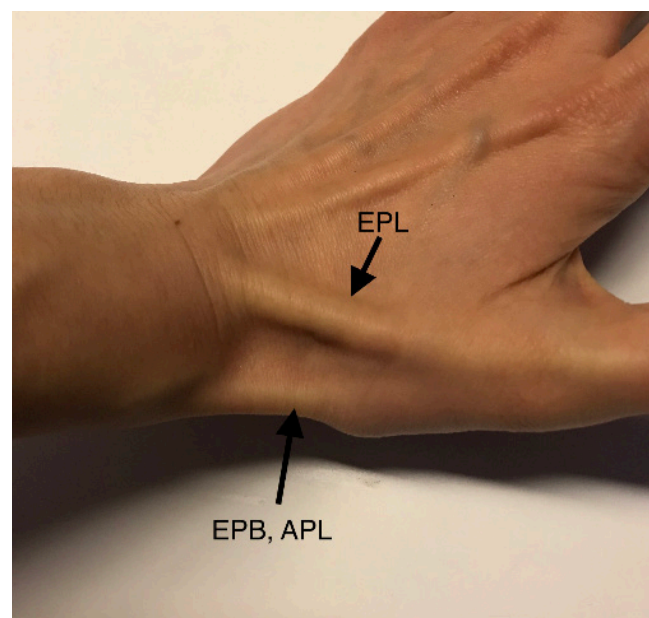



FIGURE 7:

Scaphoid tubercle tenderness

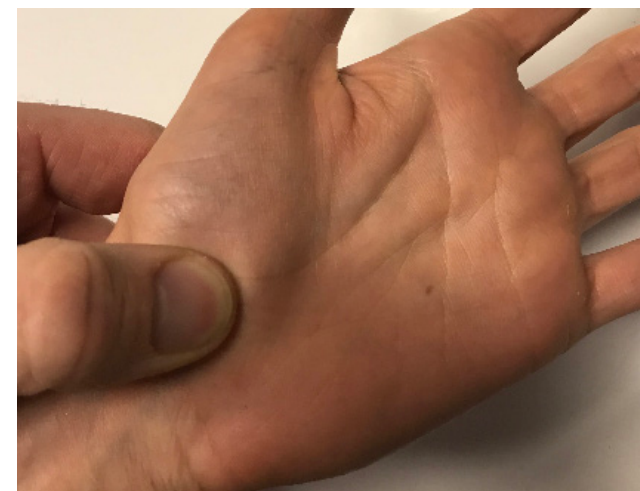

FIGURE 8:

Watson shift test



None of these tests can definitively rule in or rule out a scaphoid fracture; instead, they offer information to help steer the clinical judgment of the examiner. It should be noted that in the acute setting of a wrist injury, these tests may reproduce pain in the setting of other wrist pathology, which explains the relatively high sensitivity but low specificity. If any of these tests are positive, the patient should be treated as if they have a fractured scaphoid until proven otherwise. This will help reduce the amount of missed scaphoid fractures and related injuries.

### DIAGNOSTIC IMAGING

The typical radiographic workup for patients presenting with a scaphoid fracture includes a posteroanterior view with the wrist in neutral position, lateral view, oblique views with the wrist pronated 45 degrees, and a scaphoid view with the wrist in 45-degree ulnar deviation.<sup>2</sup> However, plain film radiographs have a false negative rate of 20% for scaphoid fractures in the acute setting, and in this

situation, it is common practice to place the patient in a thumb spica splint and repeat imaging two weeks later.<sup>1</sup> However, it is unlikely that a repeat radiograph will show a fracture on a second review.<sup>8</sup> If there is a high suspicion of a scaphoid fracture with negative plain films, other modalities such as bone scintigraphy, computed tomography, or magnetic resonance imaging should be obtained.<sup>2</sup>

It has been shown that MRI and CT have high sensitivities and specificities (MRI: 98% and 99% respectively) (CT: 94% and 96%).<sup>9</sup> When the provider is faced with the decision of ordering advanced imaging there are a few things to consider for each of the respective studies. An MRI is more sensitive and specific for scaphoid fractures, soft tissue injuries, and bone marrow edema which can be predictive of occult fractures.<sup>10</sup> An MRI is also not associated with any ionizing radiation. However, an MRI of the wrist takes roughly 30 minutes and requires the patient to remain still for the duration of the exam. If the patient has difficulties remaining still secondary to pain or if they are claustrophobic, there may be increased image artifact, making it difficult to make a diagnosis. There may also be a contraindication to obtaining an MRI if the patient has a pacemaker or other implantable metallic constructs. There are also many benefits to obtaining a CT scan as it depicts the bony anatomy better than an MRI does, the duration of the study can be significantly less than an MRI, it is typically more readily available at institutions, and has a smaller financial burden to the patient. However, sensitivity and specificity are slightly inferior to an MRI, and a CT scan is associated with ionizing radiation. Although there is an increased initial cost of treatment with each of these studies, advanced imaging has been shown to be cost-effective in the acute setting by preventing unnecessary immobilization, fewer follow-up visits, fewer long-term complications, and decreased loss of overall productivity of the patient.<sup>1</sup> The decision on which to study to order may vary on a case by case basis and depend on the availability of the resource.<sup>9,11</sup>

### COMPLICATIONS

There are two variables that determine how well a scaphoid fracture heals: time allotted between injury and proper treatment, and whether the fracture is located in the proximal, middle, or distal portion of the scaphoid.<sup>2</sup> Fractures tend to heal at different rates depending on whether the fracture is located in the distal, middle, or proximal third. Fractures in the distal segment tend to heal at a faster rate with fewer complications than if they are located more proximally. As a result of this slower course of healing, fractures in the proximal segment are more likely to result in a nonunion, which can lead to complications in the future.<sup>2</sup> Some of the complications associated with a scaphoid fracture are avascular necrosis (AVN), Dorsal Intercalated Segment Instability (DISI), delayed union, malunion, or nonunion.<sup>1</sup>

AVN is a direct result of a disruption of blood supply to any bone, and in the setting of a scaphoid fracture, it usually affects the proximal fragment.<sup>1</sup> Plain film radiographs will show sclerosis of the proximal fragment, cysts, and collapse of the affected portion of bone as the disease progresses.<sup>12</sup> However, they are often



negative in the setting of pain for the first few months and the disease is fairly progressed when evident on plain film radiograph. MRI can detect AVN at an earlier stage, and it should be ordered if there is a high index of suspicion for AVN.<sup>11</sup>

Malunion is defined by a fractured bone healing in an abnormal position, such as the two fragments being twisted, shortened, or bent relative to their anatomical position.<sup>13</sup> If a patient suffers a scaphoid fracture and does not seek treatment, or the scaphoid bone is not reduced properly prior to casting, this can lead to a malunion.<sup>13</sup> This will lead to abnormal joint structure and function, which will eventually progress to early arthritis and pain in the affected areas.

A common consequence of inadequate healing of a scaphoid fracture is nonunion. The official definition of nonunion is a failure of fracture healing at least nine months since the time of injury, and at least three months with no progression in healing.<sup>13</sup> In the setting of a nonunion there is an increased risk of post-traumatic arthritis due to disruption of the proximal carpal function known as Scaphoid Nonunion Advanced Collapse (SNAC).<sup>14</sup> If left untreated the arthritis of a SNAC wrist progresses in a rather predictable, step-wise fashion within the carpal.<sup>14</sup>

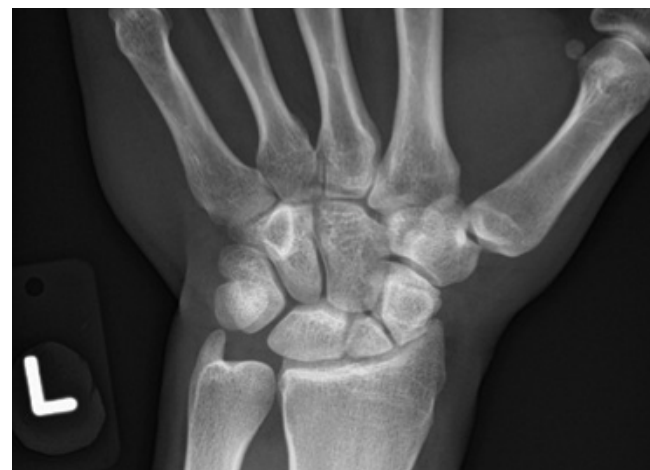The increased rate of complications, especially nonunion, may be due to a combination of the blood supply and also the relationship of the capitate articulation with the scaphoid. When stressed with load bearing, the capitate applies pressure directly to the scaphoid. This may allow more movement between the two pieces of bone with a proximal break when compared to a more distal fracture.<sup>5</sup> It is also important to consider the metabolic demands of the tissue. While there may be adequate blood for normal metabolic demands of the tissue, it is unknown if the blood supply is enough for the increased metabolic demands required for healing after trauma.<sup>15,16</sup>

## CASE OUTCOME

The patient is now 30-years-old and after being released from care with no restrictions approximately eight years ago, the patient began to ease back into his normal activities, which included returning to work in a tool and die shop, lifting weights, and racing motocross. He stopped racing motocross another year later but has continued to lift daily. He is currently asymptomatic other than some slight discomfort while lifting weights, but only with certain movements or grips. Despite being relatively asymptomatic, he chose to establish a relationship with a new hand and wrist specialist for a checkup and long-term management. During the visit with the hand and wrist specialist, plain film radiographs were taken that show a chronic scaphoid nonunion with slight sclerosis of radial-carpal interface, but the two scaphoid fragments appear to be nondisplaced (*Figure 9,10*). A CT scan was also ordered which shows the scaphoid fragments to be in good alignment with less than 1mm gap between the

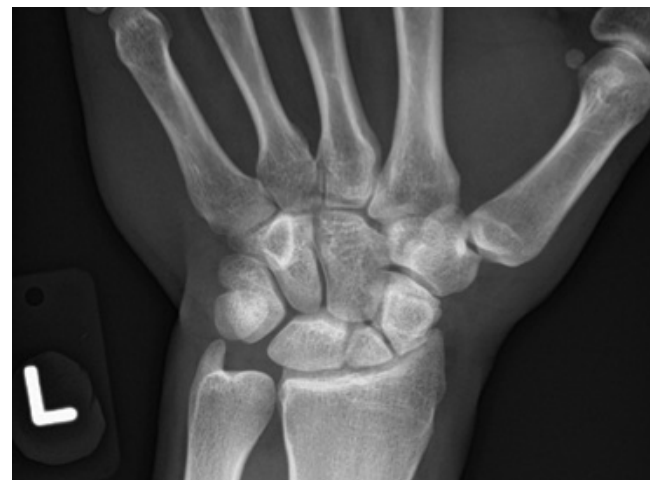**FIGURE 9:**

Plain film radiograph that shows a chronic scaphoid nonunion with slight sclerosis of radial-carpal interface



**FIGURE 10:**

Plain film radiographs showing two scaphoid fragments appearing nondisplaced

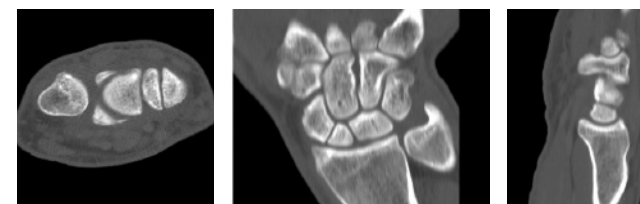

two fragments, less than 1mm of shifting, and no signs of avascular necrosis (*Figure 11*).

At this time, surgical management was decided against as the nonunion is well established and in proper alignment. In the setting of a nonunion, reducing the fragments into anatomical alignment becomes challenging due to the abundance of scar tissue within the original fracture. Due to the difficulty of aligning the fragments, the fragments already being in favorable position, and the patient being relatively asymptomatic with no changes, the surgeon felt that conservative management was the best option for this patient at this time. The patient was advised to continue with his life and follow up for additional imaging on an annual basis, or if something changes and he becomes symptomatic.

**FIGURE 11:**

CT scan showing the scaphoid fragments in good alignment



## DISCUSSION

Looking back at the initial plain film radiograph from the ED, it was clear at that time that this patient did indeed have a fracture of the scaphoid that was missed on the initial exam. As mentioned earlier, there are many complications associated with a fractured scaphoid that can be largely prevented by proper diagnosis and treatment in the acute setting. Not only can these complications cause increased morbidity for the patient, but they also significantly increase the overall cost of treatment.<sup>11,17</sup> The exact length of time between acute injury and development of long term complications can vary greatly from patient to patient. Due to the extended period of time between initial injury and development of complications, some patients can go years thinking there is no issue, only to develop chronic pain one day. This may severely impact their quality of life and can also lead to an increased financial burden on the patient.

The patient has just recently graduated from medical school and is completing the first year of his residency. Throughout school, his goal was to pursue a career in surgery. Now that he is aware of the potential for complications to develop, he has had to add this information into his decision on whether or not a surgical specialty is the best option for him, given the high possibility of one-day developing chronic wrist complications previously discussed.

Given the nature of this injury it is hard to say if this patient would have had a different outcome if he was treated properly in the acute setting, as a nonunion can still occur with proper management.<sup>1</sup> Although it is common practice that snuffbox tenderness is a broken scaphoid until proven otherwise, cases just like this one still slip through the cracks. It is these cases that we, as health care providers, must get better at preventing. If one is suspicious of a scaphoid fracture and plain film radiographs are inconclusive, there is a clear benefit to pursue advanced imaging for a more definitive answer.

## AUTHOR DISCLOSURES:

No relevant financial affiliations

## REFERENCES:

1. deWeber, Kevin. et al. Scaphoid Fractures. Uptodate.com. Dec 2017.
2. Fowler, John. Hughes, Thomas. Scaphoid Fractures. Clinics in Sports Medicine. 2015-01-01, Volume 34, Issue 1, pages 37-50, Copyright © 2015 Elsevier Inc.

3. Oehmke, M. et al. The Blood Supply of the Scaphoid Bone. The Journal of Hand Surgery, 2009. 34E: 351-357
4. Gelberman R.H., and Menon J.: The vascularity of the scaphoid bone. J Hand Surg Am 1980; 5: pp. 508-513.
5. Xiao, Zirun. Xiong, Ge. Zhang, Weiguang. New findings about the intrascaphoid arterial system. Journal of Hand Surgery. European Volume. Online. February 19, 2018
6. Ghane M R, Rezaee-Zavareh M S, Emami-Meibodi M K, Dehghani V. How Trustworthy Are Clinical Examinations and Plain Radiographs for Diagnosis of Scaphoid Fractures?, Trauma Mon. 2016 ;21(5).
7. Magee, David J. Orthopedic Physical Assessment. St. Louis, Mo: Saunders Elsevier, 2008. Page 471. Print.
8. Michla, Y. et al. Does the two-week delayed scaphoid X-ray series truly aid the diagnosis of scaphoid fractures? Injury Extra, 2010-12-01, Volume 41, Issue 12, Pages 213-213.
9. Karl, John W. Swart, Eric. Strauch, Robert J. Diagnosis of Occult Scaphoid Fractures: A Cost-Effectiveness Analysis. The Journal of Bone and Joint Surgery. 2015;97:1860-8
10. Sadineni RT, Pasumarthy A, Bellapa NC, Velicheti S. Imaging Patterns in MRI in Recent Bone Injuries Following Negative or Inconclusive Plain Radiographs. J Clin Diagn Res. 2015; 9:10-13
11. Tait, Mark A. Bracey, John W. Gaston, R Glenn. Acute Scaphoid Fractures: A Critical Analysis Review. The Journal of Bone and Joint Surgery. 2016;4(9):e3
12. Chong, A. et al. Diagnostic imaging of the hand and wrist. Plastic Surgery: Volume 6: Hand and Upper Extremity. Third Edition. 71-95.
13. Whittle, A. Paige. Malunited Fractures. Campbell's Operative Orthopaedics. Fifth Edition. Chapter 58, 3017-3080.
14. Haase, Steven. Chung, Kevin. Fractures and dislocations of the wrist and distal radius. Plastic Surgery: Volume 6: Hand and Upper Extremity. First Edition. 170-87
15. Tomlinson, Ryan E. Silva, Matthew J. Skeletal Blood Flow in Bone Repair and Maintenance. Bone Res. 2013;1(4):311-322.
16. Ghiasi MS, Chen J, Vaziri A, Rodriguez EK, Nazarian A. Bone fracture healing in mechanobiological modeling: a review of principles and methods. Bone Reports. 2017;6:87-100.
17. Weinlein, John C. Delayed Union and Nonunion of Fractures. Campbells Operative Orthopaedics. Chapter 59. 8th edition. 3081-3116.



## REVIEW ARTICLE

# An Osteopathic Approach to Greater Trochanteric Pain Syndrome

Jonathan W. Torres, DO<sup>1</sup>; Christopher Zipp, DO, FACOFP<sup>1</sup>

<sup>1</sup>Atlantic Health System, Morristown, New Jersey

## KEYWORDS:

Greater Trochanteric Pain Syndrome

Osteopathic Manipulative Medicine

Trochanteric Bursitis

ABSTRACT: Greater trochanteric pain syndrome is a common office complaint in primary care. It encompasses a constellation of clinical conditions, including greater trochanteric bursitis, teninopathies affecting the gluteus medius and gluteus minimus, inflammation of the iliotibial band and abductor-adductor imbalance. Common treatments include supportive care such as rest, ice, and compression as well as corticosteroid injections, Extracorporeal shockwave therapy and home exercise programs. Surgical interventions are reserved for refractory cases. Emerging therapies include OMM utilizing muscle energy, as well as regenerative medicine such as PRP or prolotherapy.

## INTRODUCTION

Greater trochanteric pain syndrome (GTPS) is a common complaint for which patients present to primary care physician's offices. Formerly referred to as Trochanteric Bursitis, this pain syndrome is multi-factorial. Historically GTPS was thought to be related to bursitis affecting one of several peri-trochanteric bursae. However, many studies using MRI and gross dissection have failed to demonstrate a significant presence of inflammation or distended bursae in patients suffering from GTPS. There has also been a paucity of bursitis found in GTPS patients, present on ultrasound and MRI in only 20.2% of patients.<sup>1</sup> Additional etiologies proposed for GTPS include gluteus medius and gluteus minimus tendinopathy as well as iliotibial band tendinopathy. GTPS affects 10-25% of the general population, with an annual incidence of 1.8 per 1000 patients per year, and is more common in women by a factor of 4 to 1.<sup>2,3,4</sup> There is also a comorbidity of 18-45% with low back pain patients.<sup>4</sup> GTPS may cause considerable pain, and has been clinically shown to be responsible for significantly high levels of pain and physical impairments, as well as reduced capacity for full time work and poor to fair quality of life comparable to persons with severe hip osteoarthritis.<sup>5</sup>

## CORRESPONDENCE:

Jonathan W. Torres, DO | [jonathan.torres@atlanticealth.org](mailto:jonathan.torres@atlanticealth.org)

GTPS may present with lateral hip pain which may be insidious or begin abruptly. Excessive adduction puts additional strain upon the iliotibial band (ITB) and predisposes it to injury. Excessive adduction also puts an additional strain through the gluteus medius and minimus muscles.<sup>6</sup> GTPS is a common occurrence among sedentary persons, as well as running athletes, particularly if their gait crosses the midline. In addition to these traditional GTPS populations, during the first year post stroke, 29 of 86 patients without pre-existing history of GTPS reported lateral hip pain. Of these 86 patients, 28 patients met the criterion for GTPS, suggesting a relationship between antagonistic muscles and spasticity post CVA.<sup>8</sup>

## HISTORY

Patients frequently complain of lateral hip pain, which is exacerbated by lying on the ipsilateral side or with weight bearing activities. A study seeking to identify history and physical exam factors to help discriminate OA from GTPS found that patients with GTPS could ambulate more than 30 minutes before pain onset, whereas OA patients felt pain in less than 30 minutes. Patients with GTPS also had less difficulty manipulating and putting on their shoes.<sup>9</sup> Factors highly correlated with GTPS include ipsilateral iliotibial band tenderness, ipsilateral and/or contralateral knee osteoarthritis, low back pain and leg length discrepancies.<sup>4</sup> BMI was not shown to be significantly related to GTPS.<sup>4</sup>

Likely etiologies for GTPS may include myofascial pain, trochanteric bursitis, tendinosis and rupture of the gluteus medius and minimus tendon, and external snapping hip, all of which may be contributory to the clinical syndrome. In addition, alternative etiologies such as hip osteoarthritis, lumbar radiculopathy or other spine pathology, avascular necrosis of the hip, fracture or stress fracture of the femur, slipped capital femoral epiphysis as well as referred visceral pain should be considered.<sup>10</sup>

## PHYSICAL EXAM

A thorough neurological and musculoskeletal exam including incitatory testing such as straight leg raise should be undertaken. Particular care should be given to ascertaining location, quality, severity, as well as exacerbating and alleviating factors to help eliminate alternative etiologies for their pain. Differentiation from hip osteoarthritis is an important but challenging undertaking.

There has been debate as to the reliability of physical examination in delineating GTPS from OA. The Altman Criteria (1991) clearly define OA, but do not lend information as to the diagnosis of GTPS. Suggested examinations have included the FABER test, Ober Test, the Trendelenburg Test and palpation of the greater trochanter for pain (Sometimes referred to as the "Jump sign"). Fearon et al suggest that the FABER test is reliable at distinguishing GTPS but only if the pain reproduction occurs in the lateral hip, with an odds ratio of 43.<sup>7,9</sup> They also calculated the Ober test as having an odds ratio of 13.2 irrespective of the location of pain reproduction.<sup>9</sup> Trendelenburg test was found to have 73% sensitivity and 77% specificity for detecting a tendon tear of the gluteus medius.

## IMAGING

Several imaging modalities are readily available for investigating lateral hip pain concerning for GTPS. Plain X-Ray, ultrasound and MRI each have a niche in exploring the anatomy and related conditions contributing to GTPS.<sup>19</sup>

Plain film radiography has been found useful in evaluating the arthritic nature of the joint, but also in identifying calcific tendinitis in up to 40% of patients with GTPS.<sup>3</sup> Trochanteric protrusions greater than 2 mm were found to correlate to abnormalities in the gluteus medius or minimus.<sup>3</sup> In a study by Steinert et al., 27 of 29 GTPS patients included with trochanteric surface irregularities greater than 2 mm had confirmed abductor tendon pathology.<sup>22</sup>

Ultrasound examination may show loss of fibrillary architecture suggestive of tendinopathy, as well as partial and complete tendon tears. It also is able to provide real-time evaluation of etiologies such as snapping hip.<sup>12</sup> Ultrasound is estimated to have a sensitivity of 79% and a PPV of 1.0 for gluteus medius or minimus tears and 61% sensitivity and 100% specificity for identifying bursal pathology. Ultrasound was also shown to correlate very well with intraoperative findings.<sup>12</sup> An investigation using ultrasound in the evaluation of GTPS in 877 patients found that 700 (79.8%) did not have bursitis on US, 438 (49.9%) had gluteal tendinosis, and 250 (28.5%) had thickened IT bands.<sup>1</sup>

MRI is more costly but delineates soft tissues optimally. MRI may demonstrate T2 hyper intensity in the gluteus medius, gluteus minimus or the peri-trochanteric region. MRI correlates very well with intra-operative findings, so its utilization in the preoperative period is certainly advisable. Unfortunately, due to its high sensitivity, it identified tendon pathology in 21 (53%) of asymptomatic patients in a study by Woodley et al., illustrating the high false positive rate for this modality with regards to GTPS.<sup>23</sup> Klontzas et al confirmed this finding by reviewing 174 examinations, 91 (52.3%) of which demonstrated peri-trochanteric edema, 34 (19.5%) had distended bursae. Of these 174 examinations, 78 (44.8%) had gluteus medius tendon degeneration. These patients were then examined with provocative tests described above to assess for GTPS. Only 8 of these 79 patients had pain on examination, compared with 4 of the remaining 95 patients without demonstrated degeneration.<sup>13</sup>

## TREATMENT

### Conservative Therapy

Patients with GTPS are largely successful with conservative measures in alleviating their pain. Rest, ice and anti-inflammatory medications are the cornerstones of initial management. Interventions such as home exercise routines, physical therapy, shock wave therapy, and corticosteroid injections are often effective at reducing pain in GTPS.

Home exercise routines include activity modification to avoid repetitive motions or lying on the affected side. Exercises are intended to address the weakness of the hip abductors and include piriformis stretching, ITB stretching, straight leg raises, wall squats, and gluteal strengthening. After 15 months, this resulted in an 80% remission rate. Initial results at one month, however, were delayed with only a 7% remission rate.<sup>2,14</sup>

Extracorporeal Shockwave Treatments (ESWT) was also studied. The shockwave treatment causes cortical inflammation and is believed to help initiate the healing cascade. After receiving three sessions of ESWT, patients demonstrated a 13% improvement at one month, 68% improvement at four months, and at 15 months a 74% remission rate.<sup>15</sup>

Corticosteroid Injections work very well in the short term with 75% improvement at one month, but after 15 months in the above study, patients saw only a 48% remission rate. There is no demonstrable benefit to performing GT steroid injections under fluoroscopy,<sup>16</sup> although ultrasound guided needle placement may be effective in ensuring proper needle placement, particularly in patients with larger body habitus, especially as it also offers a meaningful evaluation for tendon pathology.

### Surgical Interventions

For patients suffering refractory GTPS pain, and for those for whom a prolonged period of inactivity is intolerable, surgery is an option. There have been several proposed procedures to address GTPS. The most commonly performed is a repair of the gluteus medius or minimus tendons. If there is no gluteal tendinopathy

present, then lengthening of the ITB has been proposed as well as trochanteric bursectomy.<sup>2</sup> These interventions have good efficacy for the recalcitrant GTPS patient. In addition, a recent publication on endoscopic surgical treatment of GTPS has proven effective and safe.<sup>17</sup>

#### **Future research options: Osteopathic Treatment & Regenerative Medicine**

Osteopathic Manipulative Treatment (OMT) is intended to help support the intrinsic mechanisms for healing within the body by way of improving mechanical factors, removing restrictions to free movement and relieving musculotendinous barriers, identified as somatic dysfunctions. Osteopathic evaluation for GTPS focuses upon motion dynamics in the lumbar spine and pelvis which may be contributory to creating an aberrant motion dynamic in the femoro-acetabulum which puts excessive strain on the hip abductors.

Furthermore, OMT pays particular attention to the role of agonist-antagonist relationships. As has already been discussed, in post-stroke patients who have sudden onset of adductor-abductor imbalance, GTPS may evolve rapidly and will hinder recovery potential. Restoration of the balance within the hip should be a priority with GTPS patients. Techniques such as muscle energy are of particular utility in this condition. Muscle Energy was first described by Fred Mitchell, Sr, D.O. and involves the positioning of a body segment in a position so as to stretch the targeted muscle to its extreme dysfunctional barrier. Once in this position, a gentle contraction of the afflicted muscle is elicited from the patient, and is resisted isometrically for several seconds. This process is repeated three to five times, with repositioning in the new barrier after each serial contraction-relaxation cycle. Similarly, while performing isolytic muscle energy, the operator meets and exceeds the force supplied by the patient, resulting in a lengthening of the affected muscle during contraction, as well as resetting the dysfunctional barrier.<sup>18</sup> Isolytic Muscle Energy treatment of the adductor magnus on the ipsilateral side has a pronounced and immediate effect on Greater Trochanteric tenderness. Anecdotally, it has also shown promise in long term resolution of GTPS, especially when adductor stretching exercises are added to the home exercise regimen, and research into this approach is underway.

## **DISCUSSION**

GTPS is a complicated clinical condition that has a multitude of possible etiologies. Historically considered to be a result of greater trochanteric bursitis, imaging and intra-operative studies have failed to document significant inflammation for most GTPS patients.

Gluteus medius and Gluteus minimus tendon pathology has also been implicated, and surgical repair in refractory GTPS with coexistent tendon pathology does improve pain scoring, however, several studies have documented MRI confirmed tendon pathology in the absence of clinical symptoms, suggesting that this may only play a role in a subset of GTPS patients.

Consideration of the agonist-antagonist theory merits consideration, but to date, no studies have sought to explore this etiology for GTPS. Certainly, Koseoglu et al. have reported a prominent denovo incidence rate among post-stroke patients,<sup>8</sup> lending credence to the consideration that adductor-abductor imbalance may pre-dispose patients to the development of GTPS, ITB thickening as well as tears of the gluteus medius and minimus in their attempts to counteract the adductor magnus spasticity. OMT to address these inequities has been effective anecdotally, but clinical research to date is lacking. One study investigating the efficacy of OMT for GTPS is underway.

In addition, research exploring the value of regenerative medicine, ie. Platelet Rich Plasma (PRP) or prolotherapy has not been pursued to date. However, ESWT has been proven effective in GTPS, and the mechanism of action is analogous to that of PRP and prolotherapy, however PRP and prolotherapy allow for more targeted application of healing elements particularly if aided by ultrasound assisted needle placement.

## **SUMMARY**

GTPS is a pain condition that limits older adults in their capacity to work full time, as well as for athletes whose performance is limited by the pain. It is a complicated clinical condition which may be diagnosed effectively by a history of lateral hip pain, worse with weight-bearing, a positive FABER test with lateral hip pain or a positive Ober's test. It may be effectively treated by conservative means such as home exercise, physical therapy, corticosteroid injections, and extracorporeal shock wave therapy (ESWT). Current therapies provide either short- or long-term benefit, but should be used in combination to maximize recovery. Refractory cases may be eligible for surgical interventions. Promising clinical adjuncts include osteopathic manipulative treatments and platelet rich plasma (PRP) or prolotherapy treatments to address this condition. Further research into these emerging treatments is needed.

#### **AUTHOR DISCLOSURES:**

No relevant financial affiliations

#### **REFERENCES:**

1. Long, Susan, David Surrey and Levon Nazarian. Sonography of greater trochanteric pain syndrome and the rarity of primary bursitis. *American Journal of Radiology*. 2013: 201 1083-1086.
2. DelBuono, Angelo et al. Management of greater trochanteric pain syndrome: a systematic review. *British Medical Bulletin*. 2012; 102 115-131.
3. Chodhury, Rajat et al. Imaging and management of greater trochanteric pain syndrome. *Postgraduate Medical Journal*. 2013: 90 576-581.
4. Segal, Neil et al. Greater trochanteric pain syndrome: epidemiology and associated factors. *Archive of Physical Medicine and Rehabilitation*. 2007: 88 988-992.

5. Fearon, Angela et al. Greater trochanteric pain syndrome negatively affects work, physical activity and quality of life: A case control study. *The Journal of Arthroplasty*. 2014: 29 383-386.
6. Powers, Christopher. The influence of abnormal hip mechanics on knee injury: A biomechanical perspective. *Journal of Orthopedic and Sports Physical Therapy*. 2010: 40 42-51.
7. Lavine, Ronald. Iliotibial band friction syndrome. *Current Review of Musculoskeletal Medicine*. 2010: 3 18-22.
8. Koseoglu, Belma, Bilge Kesikburun, Oznur Oken. Greater trochanteric pain syndrome: frequency and associated factors in patients with stroke. *Topics in Stroke Rehabilitation*. 2014: 383-390.
9. Fearon, Angela et al. greater trochanteric pain syndrome: defining the clinical syndrome. *British Journal of Sports Medicine*. 2013: 47:649-653.
10. Adkins, Samuel and Richard Figler. Hip pain in athletes. *American Family Physician*. 2000: 61 2109-2118.
11. Grumet, Robert et al. Lateral hip pain in an athletic population: differential diagnosis and treatment options. *Sports Health*. 2010: 191-196.
12. Fearon, AM et al. Does ultrasound correlate with surgical or histological findings in greater trochanteric pain syndrome? *Clinical Orthopaedics and Related Research*. 2010: 468 1838-1844.
13. Klontzas, Michail and Apostolos Karantanas. Greater trochanteric pain syndrome: A descriptive MR imaging study. *European Journal of Radiology*. 2014: 83 1850-1855.
14. Mulligan, E.P. et al. Evaluation and management of greater trochanter pain syndrome. *Physical Therapy in Sport*. 2014 <http://dx.doi.org/10.1016/j.ptsp.2014.11.002>
15. Mani-Babu, Sethu et al. The Effectiveness of Extracorporeal Shock Wave Therapy in lower limb tendinopathy. *American journal of Sports Medicine*. 2014: 43 752-761.
16. Cohen, Steven. Comparison of fluoroscopically guided and blind corticosteroid injections for greater trochanteric pain syndrome: multicentre randomised controlled trial. *British medical Journal BMJ* 2009;338:b1088
17. Dominguez, Andrea et al. Clinical outcomes of trochanteric syndrome endoscopically treated. *Archive of Orthopedic Trauma Surgery*. 2015: 135 89-94.
18. Ehrenfeuchter, Walter. *Muscle Energy Approach*. Chila, Anthony. Foundations of Osteopathic Medicine. 3rd edition. 2011 LWW. Philadelphia, PA. pp 682-697.
19. McMahon, Samuel, Toby Smith and Caroline Hing. A systematic review of imaging modalities in the diagnosis of greater trochanteric pain syndrome. *Musculoskeletal Care*. 2012: 10 232-239.
20. Mallow, Michael and Levon Nazarian. Greater trochanteric pain syndrome diagnosis and treatment. *Physical Medicine and Rehabilitation Clinics North America*. 2014: 25 279-289.
21. William, Bryan and Steven Cohen. Greater trochanteric pain syndrome: A review of anatomy, diagnosis and treatment. *International Anesthesia Research Society*. 2009: 108 1662-167.
22. Steinert L, Zanetti M, Hodler J, et al. Are radiographic trochanteric surface irregularities associated with abductor tendon abnormalities? *Radiology* 2010; 257:754.
23. Woodley et al. Lateral ip pain: findings from magnetic resonance imaging and clinical examinations. *Journal of Orthopedic Sports Physical Therapy*. 2008: 6 313-328.



## REVIEW ARTICLE

# Clinical Symptoms Associated with Asymptomatic Peripheral Arterial Disease: A Literature Review

Arthur Tarricone, MPH<sup>1</sup>; Ruben Dovlatyan, OMS I<sup>1</sup>; Karla De La Mata, BS<sup>2</sup>; Joseph S. Coppola, BS<sup>2</sup>; Prakash Krishnan, MD, FACC<sup>2</sup>

<sup>1</sup>Icahn School of Medicine at Mount Sinai, New York, NY

<sup>2</sup>New York College of Podiatric Medicine, New York, NY

## KEYWORDS:

Neuropathy

Peripheral arterial disease

Primary care

Psoriasis, onychomycosis

## ABSTRACT

**Background:** The incidence and prevalence of Peripheral Arterial Disease (PAD) is rising, yet physician awareness is insufficient. This review aims to increase awareness and detection of asymptomatic PAD in primary care, dermatologic, or podiatric practices through observable symptoms and subtle pathologies concomitant with PAD so patients may benefit from preliminary screening.

**Methods:** A systematic review of Google Scholar for literature establishing a link between PAD and observable symptoms or examinable pathologies that could be ascertained in primary care.

**Results:** 31 manuscripts were included. Four discussed examinable symptoms of PAD. Significant ORs predicted PAD by ABI < 0.9 for cool skin, cyanosis, or lower-extremity wounds or sores (6.4, 3.8, 6.0, respectively). Four papers described clinical tests, with diminished capillary refill time, venous filling time, unilateral absence of foot pulses, mild unilateral weakness in foot pulses (OR 8.6), auscultation of femoral bruit (OR 7.8), weak unilateral femoral pulse (OR 3.7), or absent and normal femoral pulses in opposite legs (OR 6.1) significantly predicting PAD. Four papers discussed PAD as an independent predictor of onychomycosis with risk odds-ratio (ROR) 4.8. Six papers investigated onychomycosis' relation to psoriasis, while another six mentioned psoriasis predicting PAD (OR 1.98; RR 2.6). Four studies demonstrated diminished peripheral nerve performance in PAD, and five mentioned PAD-related ulceration and the disease's ability to disrupt wound-healing (OR 2.31).

**Conclusion:** PAD is underdiagnosed, an issue that may be improved through increasing educational outreach awareness of the asymptomatic disease, and ability to detect subtle risk factors, symptoms, and pathologies predictive of PAD.

## ABBREVIATIONS

PAD: peripheral arterial disease

OR: Odds ratio

LR: Likelihood ratio

CLI: Critical limb ischemia

NCS: Nerve conduction study

SFA: Superficial femoral artery

DP: Dorsalis pedis (artery)

ABI: Ankle-brachial index

ROR: Risk odds ratio

RR: Relative risk

LEA: Lower extremity amputation

EMG: Electromyography

PCP: Primary care practitioner

PT: Posterior tibial (artery)

## INTRODUCTION

Peripheral arterial disease (PAD) affects 8.5 million people in the US and is characterized by a loss or reduction of perfusion to the legs caused by atherosclerosis.<sup>1,2</sup> CDC and NIH data has demonstrated a correlation between risk of PAD diagnosis and age. As of 2016, PAD's prevalence has risen to an estimated 20% of individuals over 60.<sup>3,4</sup> Physician awareness and early diagnosis continues to be challenging largely because the majority of PAD cases are asymptomatic. Epidemiologic projections claim that PAD's prevalence is 27 million individuals in North America and Europe, 16.5 million of which are asymptomatic cases.<sup>5</sup> This literature review intends to increase awareness of clinically observable symptoms and more subtle associations for asymptomatic peripheral arterial disease that can be recognized in a primary care setting. Ideally, augmenting primary care physicians' ability to detect patients at-risk of PAD in conjunction with heightened ability to detect signs indicative of the disease through the patient interview and hands-on techniques may increase the patient's odds of a favorable outcome.

## METHODS

A search for relevant literature was carried out of Google Scholar in December 2017 and January 2018. Below are the specific keyword searches and aggregate number of results. Bracketed phrases were entered into Google Scholar's advanced search function, "with the exact phrase." All searches excluded publications before the year 2000. As a basis, the most recent 2016 AHA/ACC Guideline on the Management of Patients with Lower Extremity PAD (see reference 1) was included in the review, as was reference 2, the 2005 ACC/AHA Guidelines article due to the sheer number of sources citing this paper. When an article was read because it was referenced within one of the manuscripts brought up by these methods, it was also included in this review. For example, reference 11 was reviewed and cited, a source of reference 1.

Articles were included that mentioned peripheral arterial disease and any physically observable symptom or examinable pathology that could be determined in a primary care setting, along with research-based evidence supporting the link between PAD and this pathology.

**1. Include:** [peripheral arterial disease]; detection; awareness; dermatology; asymptomatic; symptomatic; risk factor; epidemiology.

Exclude: Asia; Africa. 48 results.

The purpose of this introductory search was to establish a baseline of information regarding the symptoms of PAD or concomitant pathologies that were quickly observable in a typical Primary Care Physician's (PCP) office. Articles were included if they had direct mention of PAD and relation to any abnormal, easily observable physical phenomenon that could be observed without special equipment, e.g. discoloration of a body part. Asia and Africa were exclusion terms due to this review's scope of PAD in the United States. This search directly yielded references 5, 6, 9, and 10. Reference 6 provided a link to reference 36, and reference 10 provided reference 8 by way of the aforementioned method of

including relevant sources cited within search results. Reference 36 was only mentioned in the discussion section of this review.

**2. Include:** [peripheral arterial disease]; [critical limb ischemia]; [diabetic foot]; [wound healing]; ulcer; vascular; management; identification; skin; assessment classification.

Exclude: meta; culture; epidemiology; revascularize. 19 results.

This search served the purpose of exploring the differences in wound healing and ulceration in PAD, as well as in more severe cases of Critical Limb Ischemia (CLI). This search provided references 33 and 34. Reference 34, the baseline results from the EURODIALE study, prompted a search for this specific study on google scholar and the subsequent inclusion of reference 35, the 1-year follow-up of EURODIALE in this review. A wealth of microbiological studies involving cultured ulcer tissue, as well as meta-analyses, which were deemed irrelevant to the topic of this review, necessitating "meta" and "culture" as exclusion terms.

**3. Include:** [peripheral arterial disease]; dermatology; skin; examination; risk factor; epidemiology.

Exclude: outcome; Asia; Africa; receptor. 37 results in English.

This final search was meant to narrow in on specific diseases comorbid with PAD, branching into other specialties. A wealth of protein receptor studies irrelevant to the topic of this review necessitated "receptor" as an exclusion term. References 7, 14, 16, 23, 28, and 32 were found directly in this search. References 17-20 were found within reference 16, all discussing the relation between onychosis and psoriasis within the context of PAD. Reference 23 provided information on the link between PAD and psoriasis, citing references 22, 25, 26, and 27 within this review. Reference 25, in turn, provided reference 24, discussing the microbiological evidence of the interplay between PAD and psoriasis. Reference 21 was cited in both references 17 and 18. Reference 15 was cited within reference 14.

**4. Include:** [peripheral arterial disease]; [nerve conduction study]; [peripheral neuropathy].

116 results in English

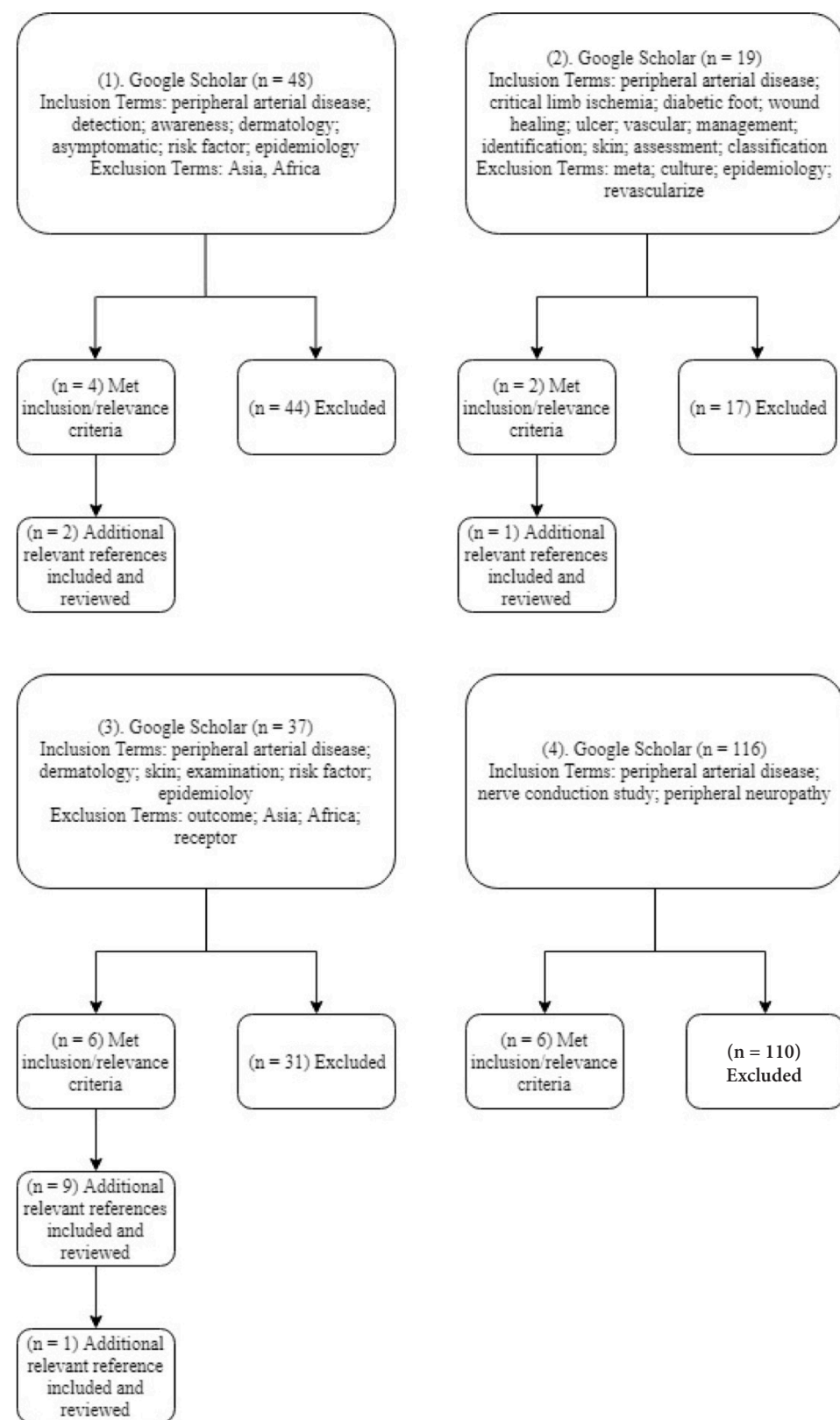
After the inclusion of Reference 28, a study on the relationship between PAD and peripheral nerve function, the author interested in exploring the relationship further through the above search protocol. Direct studies were included in this review if they explored the relationship between PAD and peripheral nerve function, particularly if examinable by Nerve Conduction Study (NCS). Studies were excluded if they involved participants in a PAD group that exhibited progressed ischemic symptoms like gangrene or ulceration of the foot. This search protocol produced references 29 – 31, all studies illuminating a significant relationship between PAD and observable abnormalities on NCS.

## RESULTS

A total of 31 sources were retrieved for review and discussion in this literature review using the methods section outlined above.

## CORRESPONDENCE:

Arthur Tarricone, MPH | arthur.tarricone@mountsinai.org

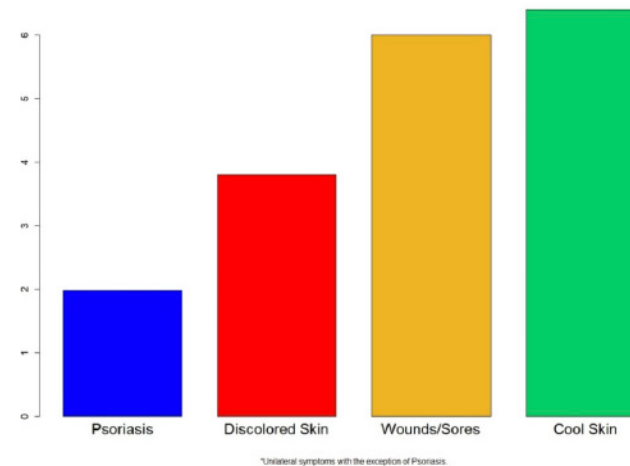


Six sources were included from Search 1, three sources from Search 2, and a total of 16 sources were included from Search 3. Three sources were included from Search 4. The two sources included in this section not obtained through the three outlined search algorithms are the 2016 and 2005 ACC/AHA Guidelines for the Management of Patients With Peripheral Arterial Disease, references 1 and 2, respectively.

**PHYSICAL EXAM**

A total of four reviewed papers discussed symptoms discoverable through physical examination requiring no specialized equipment that indicated PAD. Examination of the lower extremities for “absence of hair growth,” namely on the toes, “perspiration, dry skin, and cool temperature” are easily identifiable and may indicate subtle changes in physiology as a result of reduced lower-extremity perfusion.<sup>6</sup> Cooler, bluer skin (cyanosis) is one common sign of PAD, though a more severely ischemic foot can appear pink and warm “because of arteriovenous shunting”.<sup>7</sup> A large-scale study on 2,455 Netherlandish participants demonstrated significant ORs for predictability of PAD by Ankle-Brachial Index (ABI) < 0.9 from cool skin (OR 6.4), discolored skin (particularly cyanosis, OR 3.8), and wounds or sores on the lower extremity (OR 6.0) (Figure 1).<sup>8</sup> “Calf atrophy, dependent rubor and elevation pallor, loss of hair over the dorsum of the foot, thickening of the toenails, and shiny, scaly skin due to the loss of subcutaneous tissue...are indications of severe tissue ischemia,” requiring immediate evaluation and treatment.<sup>9</sup>

**FIGURE 1:**  
OR Comparison of PAD Risk Factor\*

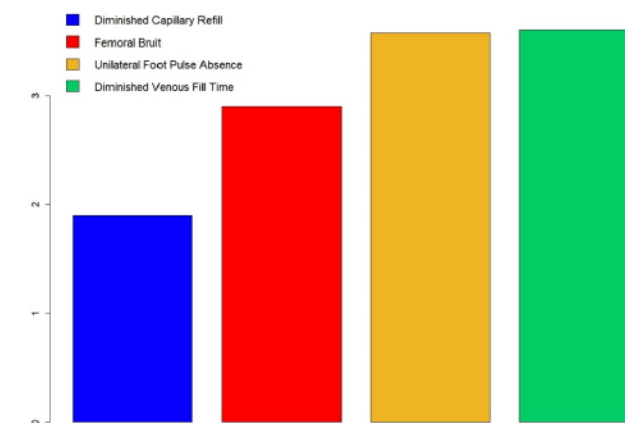


**CLINICAL TECHNIQUES**

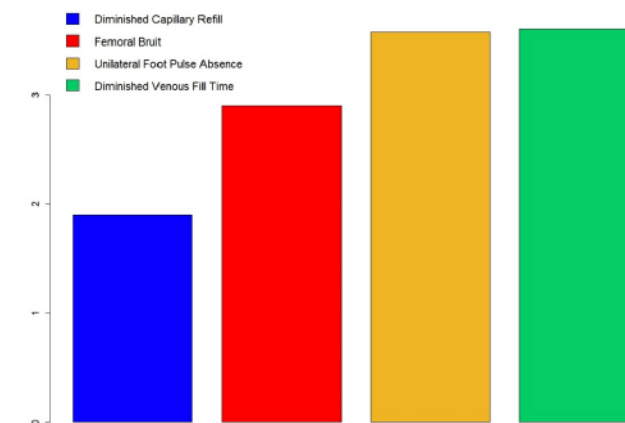
Four papers in this review discussed palpation techniques performable by all general practitioners with common medical equipment. Mohler III’s literature review claims superficial femoral artery (SFA) stenosis, the most common form of PAD, is typically characterized by normal femoral pulse and absent distal pulses. In the Buerger Test, the clinician instructs the patient to lie supine, and slowly elevates the leg evaluating for the development of pallor in the limb (a positive test), and noting the angle of the leg at

which pallor develops. Though this review did not find any studies directly comparing the effectiveness of the Buerger Test to an ABI and predictability of PAD, the Buerger Test can indicate issues with circulation to the leg through determining the dependent angle for circulation, and easily segway into an exam for venous filling time.<sup>6</sup> Capillary refill time after relieving manual pressure to the plantar aspect of the great toe is associated with PAD (LR 1.90), as is venous filling time greater than 20 seconds (LR 3.6) to a vein identified in the Buerger test with the patient now sitting upright with legs hanging down.<sup>10</sup> Absence of unilateral posterior tibial (PT) and dorsalis pedis (DP) pulses predict ABI < 0.9 (LR 3.57), as does auscultation of a femoral bruit (LR 2.90)<sup>11</sup> (Figure 2). The study on Netherlandish patients demonstrated predictability of ABI < 0.9 in patients with normal femoral pulse in one leg and absent in the other (OR 6.1), weak unilateral femoral artery pulse (OR 3.7), and femoral bruit (OR 7.8). Additionally, if one foot lacked both DP and PT pulse or if one of these was absent while the other weakened, this was also found to be a strong, significant predictor for ABI < 0.9 (OR 30.4), as was any unilateral weakened foot pulse (OR 8.6)<sup>8</sup> (Figure 3).

**FIGURE 2:**  
LR Comparison of PAD Detection Methods



**FIGURE 3:**  
OR Comparison of Pulse Palpation Techniques for PAD Detection





## ONYCHOMYCOSIS

Four sources in this review directly demonstrated an epidemiological relationship between PAD and the fungal toenail infection, onychomycosis. Identified by abnormal toenail growth and confirmed through lab pathology<sup>12</sup>, onychomycosis was shown to affect 35.1% of patients visiting a vascular clinic for PAD, confirmed by ABI < 0.8. In another study, 83.3% of smokers of at least two packs per day suffered from onychomycosis, and PAD remained a predictor of onychomycosis even when adjusting for the effect of smoking (ROR 4.8)<sup>13</sup>. Onychomycosis affected 22% of elderly diabetic patients in another.<sup>14</sup> Patients with diabetes (the other token risk factor for PAD besides age) were three times as likely to suffer from onychomycosis than those without diabetes.<sup>15</sup>

## PSORIASIS/ONYCHOMYCOSIS

Six papers discovered in this review mentioned an epidemiological relationship between onychomycosis and psoriasis. Many studies debate the exact nature of the relationship between onychomycosis and psoriasis, as demonstrated by Szepietowski and Salomon's 2007 literature review.<sup>16</sup> Gupta and colleagues found onychomycosis in 13% of psoriatic patients, and a 27% presence of any fungal nail infection in psoriatic patients with any nail abnormality in 1997.<sup>17</sup> Yeast-like fungi and molds were uncommon. In 2004, Hamnerius and colleagues found no difference in prevalence of onychomycosis in psoriatics vs. non-psoriatics.<sup>18</sup> Larsen and colleagues showed no difference in 2003 in prevalence of onychomycosis in their psoriatic vs non-psoriatic subjects, but they did find a higher percentage of yeast colonization in those suffering the toenail infection in the psoriasis group.<sup>19</sup> Stander and colleagues found a large difference in presence of yeasts in subjects with directly psoriatic nails (23.9%) vs. psoriatics without nail abnormalities (6.1%) in 2001<sup>20</sup>, with similar results in Staberg and colleagues' 1983 study.<sup>21</sup>

## PSORIASIS

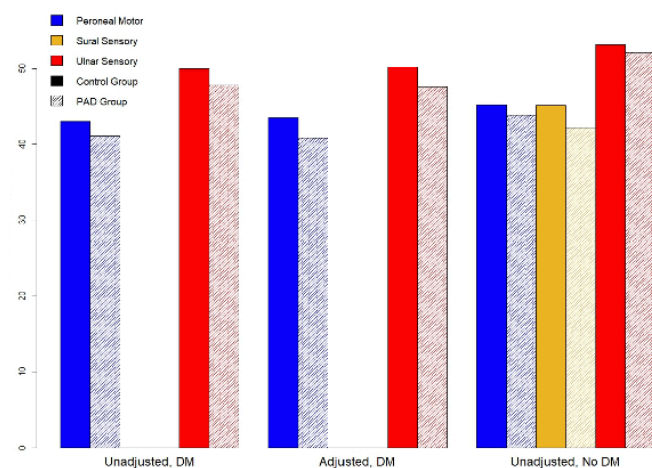
Six additional studies confirmed concomitance between psoriasis and PAD or classic PAD-related risk factors. A major data review of the Miami VA Medical Center Database found that psoriasis carried an OR of 1.98 to PAD, as determined by previously entered ICD-9-CM codes in the database.<sup>22, 23</sup> Early electron microscope studies show "microscopic abnormalities in the cutaneous blood vessels of psoriatic patients,"<sup>24</sup> and suggest a relative risk of 2.6 for PAD if a diagnosis of psoriasis is present.<sup>25</sup> Another study found increased hazard ratios (HR) in psoriatic participants for many PAD risk factors and associated complications: Diabetes (1.33), hypertension (1.09), obesity (1.18), hyperlipidemia (1.17), myocardial infarction (1.21), angina (1.20), atherosclerosis (1.28), peripheral vascular disease (1.29), and stroke (1.12).<sup>26</sup> Another study found that risk of stroke was elevated by 44% in those with "severe psoriasis."<sup>27</sup>

## PERIPHERAL NERVE CONDUCTION STUDIES

Four direct studies were found illuminating a relationship between PAD and peripheral nerve performance. Participants without diabetes demonstrated significantly diminished peroneal motor, sural sensory, and ulnar sensory nerve conduction velocity, amplitude, and onset latency ( $p < 0.05$ ) in unadjusted analyses. The effect persisted in unadjusted analyses of patients with diabetes but only in conduction velocity of the peroneal motor nerve, and velocity and latency of the ulnar sensory nerve. Though diabetes' peripheral neurodegenerative effect may be a confounding variable in the effect of PAD on nerve conduction, this study suggests the possibility of an independent effect of PAD. After adjusting for several confounding variables including but not limited to age, sex, and smoking status, nerve function was still significantly diminished in the peroneal motor and ulnar sensory conduction velocity, and sural sensory impulse amplitude<sup>28</sup> (Figure 4).

FIGURE 4:

Significant Effects of PAD on Nerve Conduction Velocity



In a study on participants aged 60+, individuals determined to have PAD by ABI < 0.9 were found to have slower nerve conduction velocity of the peroneal nerve (44.16 vs. 43.04 m/s,  $p = 0.003$ ), consistent with findings in McDermott et al, 2006.<sup>29</sup> Adding to the evidence of the interplay between diabetes and PAD on peripheral nerve abnormalities, a study on 240 Chinese participants categorized their subjects into three groups: confirmed diabetes (determined by presenting symptoms and abnormalities on NCS), subclinical diabetes (symptoms consistent with diabetic peripheral neuropathy, but no abnormal findings on NCS), and those without diabetic peripheral neuropathy (control). The study found significantly higher prevalence of PAD as determined by ABI < 0.9 in their confirmed group than either the subclinical or control group (30%, 7.7%, and 3.4%, respectively).<sup>30</sup> Finally, a study recruited patients in Greece and determined early-stage PAD through clinical decisions based on patient history and physical exam. Lack of ABI in the determination of PAD may detract from the study's validity. In any case, a dynamic F-wave study, a specialized test that can be added to a routine NCS, demonstrated to the experimenters that

participants with PAD experienced significantly greater F-wave duration in the tibial motor nerve than pre-exercise (average  $16.3 \pm 3.5$  vs.  $13.9 \pm 2.9$ ,  $p = 0.017$ ). The non-PAD control group experienced no difference pre and post-exercise.<sup>31</sup>

## FOOT ULCERATION

Five papers in this review discussed the characteristics of ulcers that specifically result from or relate to PAD. PAD specifically causes arterial ulcers<sup>32</sup>, appearing "punched out," with a deep, necrotic wound bed typically on the lateral malleolus, tibial region, or other pressure points. Unrelated venous ulcers are shallower, containing "granulation tissue or yellow fibrin," and are commonly between the lower calf and medial malleolus.<sup>7</sup> Arterial ulcers, particularly in patients with severely diminished ABIs, do not heal properly without revascularization.<sup>33</sup> The Eurodiale study on diabetic foot ulcers examined the relationship between PAD and wound-healing, finding PAD by ABI < 0.9 in 49% of participants presenting with diabetic foot ulcers, and were more likely to have infection in their ulcer than non-PAD participants (63% vs. 53%,  $p < 0.05$ ).<sup>34</sup> The one-year follow-up of this study found that 23% of participants had still not yet healed, PAD being an independent predictor of non-healing with OR 2.<sup>31, 35</sup>

## DISCUSSION

Despite the rising incidence of PAD, physician awareness can be improved; an Illinois survey of internists presented with a hypothetical case of an obese 65-year-old male with hypertension, showed that only 37% responded that they would attempt to obtain a history concerning PAD.<sup>36</sup> Furthermore, the US PARTNERS Program study including data on 6,417 diabetic smokers between ages 50 and 69 determined that of the 29% of participants with PAD, 55% received their diagnosis only from the ABI administered at screening.<sup>9</sup>

Claudication is the classic finding in symptomatic PAD, however, this can be masked by patient changes in lifestyle. A detailed history and physical exam may be able to determine patient changes in physical activity due to asymptomatic PAD alerting the physician to PAD workup. This review illuminates certain clinically observable symptoms, including examinable skin abnormalities, findings in clinical techniques, onychomycosis, psoriasis, and NCS findings that may be used as a clue to underlying PAD.

Asymptomatic diagnosis can be made by positive ABI, a clinical measure of systolic pressure at the ankle to systolic pressure at the arm obtained with a pressure cuff.<sup>1, 2</sup> Having been demonstrated to be over 90% specific and sensitive,<sup>37, 38</sup> it is explicitly recommended by the American College of Cardiology and American Heart Association for accurate PAD diagnosis.<sup>1, 2</sup>

The under-diagnosis of asymptomatic PAD is an issue in United States healthcare. End stage PAD will progress to Critical Limb Ischemia (CLI) and 20% of patients diagnosed with CLI die within 1 year, while another 20% suffer a lower-extremity amputation (LEA) within one year. Of all patients with PAD presenting with claudication, 5% progress within five years to receive LEA.<sup>39</sup> Roughly

15% of PAD patients at any stage presenting with non-healing diabetic foot ulcers undergo a major LEA within one year, of which 15% die within one year and nearly 50% within 5 years.<sup>40</sup> PAD can also result in complications like stroke, myocardial infarction, and angina, but at its core, a PAD diagnosis is associated with a five-year death rate of 33.2%.<sup>41</sup>

This systematic review was conducted in order to increase awareness of less-common pathologies or physically observable symptoms comorbid with asymptomatic PAD in primary care. Increased awareness can lead to early diagnosis, which may improve patient outcome.

## CONCLUSION

There are several predictive findings of PAD that can be identified in the primary care setting, including dermatological abnormalities, positive findings on several clinical techniques, and presence of psoriasis, onychomycosis, or NCS abnormalities. Early diagnosis of PAD may lead to improved patient outcomes. PCPs are functionally patients' first line of defense within the bounds of medical practice against disease. Given the growing incidence and prevalence of PAD in the US population, difficulty in diagnosing asymptomatic disease until late stages, as well as the dire late-stage prognosis of PAD, it is paramount that PCPs be aware of the disease's scope, and take the extra time in their practice to palpate for lower-extremity pulses, auscultate bruits, perform a thorough physical exam, and ask relevant clinical questions in the patient interview so that signs of asymptomatic disease can be detected earlier. Such steps may be key in the preventing complications, particularly in at-risk populations such as the elderly, diabetics, and smokers. These practices, if put into place regularly, may lead to earlier-stage diagnosis, subsequent treatment, and finally improved prognoses in PAD.

## AUTHOR DISCLOSURES:

No relevant financial affiliations

## REFERENCES:

- Gerhard-Herman MD, Gornik HL, Barrett C, et al. 2016 AHA/ACC Guidelines on the management of patients with lower extremity peripheral artery disease: Executive Summary: A report of the American College of Cardiology/American Heart Association task force on clinical practice guidelines. *Journal of the American College of Cardiology*. 2017;69:1465-1508. <http://circ.ahajournals.org/content/135/12/e686#T4>
- Hirsch AT, Haskal ZJ, Hertzler NR, et al. ACC/AHA 2005 Guidelines for the management of patients with peripheral arterial disease (Lower extremity, renal, mesenteric, and abdominal aortic): A collaborative report from the American Association for Vascular Surgery/Society for Vascular Surgery, Society for Cardiovascular Angiography and Interventions, Society for Vascular Medicine and Biology, Society of Interventional Radiology, and the ACC/AHA Task Force on Practice Guidelines (Writing Committee to Develop Guidelines for the Management of Patients with Peripheral Arterial Disease). *Journal of the American College of Cardiology*. 2006;47(6):e1-e192. <https://www.sciencedirect.com/science/article/pii/S0735109706004530>

3. Criqui MH, Fronek A, Barrett-Connor E, et al. The prevalence of peripheral arterial disease in a defined population. *Circulation*. 1985;71(3):510-515. <http://circ.ahajournals.org/content/71/3/510>
4. United States. Centers for Disease Control and Prevention. Peripheral Artery Disease (PAD) Fact Sheet, 2016. [https://www.cdc.gov/dhdsp/data\\_statistics/fact\\_sheets/fs\\_pad.htm](https://www.cdc.gov/dhdsp/data_statistics/fact_sheets/fs_pad.htm).
5. Belch JFF, Topol EJ, Agnelli G, et al. Critical issues in peripheral arterial disease detection and management: A call to action. *Arch Intern Med*. 2003;163(3):884-892. <https://jamanetwork.com/journals/jamainternalmedicine/fullarticle/215379>
6. Mohler III ER. Peripheral arterial disease: Identification and implications. *Arch Intern Med*. 2003;163(19):2306-2314. <https://jamanetwork.com/journals/jamainternalmedicine/fullarticle/216210>
7. Singer AJ, Tassiopoulos A, Kirsner RS. Evaluation and management of lower-extremity ulcers. *New England Journal of Medicine*. 2017;377:1559-1567. <http://www.nejm.org/doi/full/10.1056/NEJMra1615243>
8. Stoffers HEJH, Kester ADM, Kaiser V, et al. Diagnostic value of signs and symptoms associated with peripheral arterial occlusive disease seen in general practice: A multivariable approach. *Medical Decision Making*. 1997;17(1):61-70. <http://journals.sagepub.com/doi/abs/10.1177/0272989X9701700107>
9. Hirsch AT, Criqui MH, Treat-Jacobson D, et al. Peripheral arterial disease detection, awareness, and treatment in primary care. *JAMA*. 2001;286(11):1317-1324. <https://jamanetwork.com/journals/jama/fullarticle/194205>
10. Khan NA, Rahim SA, Anand SS, et al. Does the Clinical Examination predict lower extremity peripheral arterial disease? *JAMA*. 2006;295(5):536-546. <https://jamanetwork.com/journals/jama/fullarticle/202296>
11. Cournot M, Boccalon H, Cambou JP, et al. Accuracy of the screening physical examination to identify subclinical atherosclerosis and peripheral arterial disease in asymptomatic subjects. *Journal of Vascular Surgery*. 2007;47(6):1215-1221. [http://www.jvascsurg.org/article/S0741-5214\(07\)01350-X/abstract](http://www.jvascsurg.org/article/S0741-5214(07)01350-X/abstract)
12. Elewski BE. Onychomycosis: Pathogenesis, Diagnosis, and Management. *Clinical Microbiology Reviews*. 1998;11(3):415-429. <http://cmr.asm.org/content/11/3/415.full>
13. Gupta AK, Gupta MA, Summerbell RC, et al. The epidemiology of onychomycosis: possible role of smoking and peripheral arterial disease. *Journal of the European Academy of Dermatology and Venereology*. 2000;14(6):466-469. <http://onlinelibrary.wiley.com/doi/10.1046/j.1468-3083.2000.00124.x/full>
14. Saunte DML, Holgersen JB, Hædersdal M, et al. Prevalence of toe nail onychomycosis in diabetic patients. *Acta Dermato-Venerologica*. 2006;85(5):425-428. <http://www.ingentaconnect.com/content/mjl/adv/2006/00000086/00000005/art00009>
15. Dogra S, Kumar B, Bhansali A, et al. Epidemiology of onychomycosis in patients with diabetes mellitus in India. *International Journal of Dermatology*. 2002;41(10):647-651. <http://onlinelibrary.wiley.com/doi/10.1046/j.1365-4362.2002.01528.x/full>
16. Szepletowski JC, Salomon J. Do fungi play a role in psoriatic nails? *Mycoses*. 2007;50(6):437-442. <http://onlinelibrary.wiley.com/doi/10.1111/j.1439-0507.2007.01405.x/full>
17. Gupta AK, Lynde CW, Jain HC, et al. A higher prevalence of onychomycosis in psoriatics compared with non-psoriatics: a multicentre study. *British Journal of Dermatologists*. 1997; 136(5):786-789. <http://onlinelibrary.wiley.com/doi/10.1046/j.1365-2133.1997.6771624.x/full>
18. Hamnerius N, Berglund J, Faergemann J. Pedal dermatophyte infection in psoriasis. *British Journal of Dermatologists*. 2004; 150(6):1125-1128. <http://onlinelibrary.wiley.com/doi/10.1111/j.1365-2133.2004.05959.x/full>
19. Larsen GK, Haedersdal M, Svejgaard EL. The prevalence of onychomycosis in patients with psoriasis and other skin diseases. *Acta Dermato-Venerologica*. 2003;83(3):206-209. <https://pdfs.semanticscholar.org/e8ca/d97ebb98b89f5a9c71925d49754664c24ec3.pdf>
20. Ständer H, Ständer M, Nolting S. Incidence of fungal involvement in nail psoriasis. *Hautarzt*. 2001;52(5):418-422. <https://link.springer.com/article/10.1007%2Fs001050051335>
21. Staberg B, Gammeltoft M, Onsberg P. Onychomycosis in patients with psoriasis. *Acta Dermato-Venerologica*. 1983;63(5):436-438. [https://medicaljournals.se/acta/content\\_files/download.php?doi=10.2340/00015555463436438](https://medicaljournals.se/acta/content_files/download.php?doi=10.2340/00015555463436438)
22. Prodanovich S, Kirsner RS, Kravetz JD, et al. Association of psoriasis with coronary artery, cerebrovascular, and peripheral vascular diseases and mortality. *Arch Dermatol*. 2009;145(6):700-703. doi:10.1001/archdermatol.2009.94. <https://jamanetwork.com/journals/jamadermatology/fullarticle/712050>
23. Vena GA, Vestita M, Cassano N. Psoriasis and cardiovascular disease. *Dermatologic Therapy*. 2010;23(2):144-151. <http://onlinelibrary.wiley.com/doi/10.1111/j.1529-8019.2010.01308.x/full>
24. Braverman IM. Electron microscopic studies of the microcirculation in psoriasis. *Journal of Investigative Dermatology*. 1972;59(1):91-98. <https://www.sciencedirect.com/science/article/pii/S0022202X15481825>
25. McDonald CJ, Calabresi P. Psoriasis and occlusive vascular disease. *British Journal of Dermatology*. 1978;99(5):469-475. <http://onlinelibrary.wiley.com/doi/10.1111/j.1365-2133.1978.tb02012.x/epdf>
26. Kaye JA, Li L, Jick SS. Incidence of risk factors for myocardial infarction and other vascular diseases in patients with psoriasis. *British Journal of Dermatology*. 2008;159(4):895-902. <http://onlinelibrary.wiley.com/doi/10.1111/j.1365-2133.2008.08707.x/full>
27. Gelfand JM, Dommasch ED, Shin DB, et al. The risk of stroke in patients with psoriasis. *Journal of Investigative Dermatology*. 2009;129(10):2411-2418. <https://www.sciencedirect.com/science/article/pii/S0022202X15341063?via%3Dihub>
28. McDermott MM, Sufti R, Nishida T, et al. Lower extremity nerve function in patients with lower extremity ischemia. *Arch Intern Med*. 2006;166(18):1986-1992. <https://jamanetwork.com/journals/jamainternalmedicine/fullarticle/411045>
29. McDermott MM, Guralnik JM, Albay M, et al. Impairments of Muscles and Nerves Associated with Peripheral Arterial Disease and Their Relationships with Lower Extremity Functioning: The InCHIANTI Study. *Journal of the American Geriatrics Society*. 2004;52(3):405-410. <http://onlinelibrary.wiley.com/doi/10.1111/j.1532-5415.2004.52113.x/full>
30. Unmar Y, Zafar MI, Gao FJ. Factors associated with peripheral neuropathy in type 2 diabetes: Subclinical versus confirmed neuropathy. *Journal of Huazhong University of Science and Technology [Medical Sciences]*. 2017;37(3):337-342. <https://link.springer.com/content/pdf/10.1007%2Fs11596-017-1737-5.pdf>
31. Argyriou AA, Tsolakis I, Papadoulas S, et al. Dynamic F wave study in patients suffering from peripheral arterial occlusive disease. *Acta Neurologica Scandinavica*. 2007;115(2):84-89. <http://onlinelibrary.wiley.com/doi/10.1111/j.1600-0404.2006.00725.x/full>
32. Dissemond J, Körber A, Grabbe S. Differential diagnosis of leg ulcers. *Journal der Deutschen Dermatologischen Gesellschaft*. 2006;4(8):627-634. <http://onlinelibrary.wiley.com/doi/10.1111/j.1610-0387.2006.06052.x/full>

33. Haffner J, Schaad I, Schneider E, et al. Leg ulcers in peripheral arterial disease (arterial leg ulcers): Impaired wound healing above the threshold of chronic critical limb ischemia. *Journal of the American Academy of Dermatology*. 2000;43(6):1001-1008. [http://www.jaad.org/article/S0190-9622\(00\)32178-8/pdf](http://www.jaad.org/article/S0190-9622(00)32178-8/pdf)
34. Prompers L, Huijberts M, Apelqvist J, et al. High prevalence of ischaemia, infection, and serious comorbidity in patients with diabetic foot disease in Europe. Baseline results from the Eurodiale study. *Diabetologia*. 2007;50(1):18-25. <https://link.springer.com/article/10.1007/s00125-006-0491-1>
35. Prompers L, Schaper N, Apelqvist J, et al. Prediction of outcome in individuals with diabetic foot ulcers: focus on the differences between individuals with and without peripheral arterial disease. The EURODIALE Study. *Diabetologia*. 2008;51(5):747-755. <https://link.springer.com/article/10.1007/s00125-008-0940-0>
36. McLafferty RB, Dunnington GL, Mattos MA, et al. Factors affecting the diagnosis of peripheral vascular disease before vascular surgery after referral. *Journal of Vascular Surgery*. 1999;31(5):870-879. [http://www.jvascsurg.org/article/S0741-5214\(00\)25741-8/fulltext#section.0020](http://www.jvascsurg.org/article/S0741-5214(00)25741-8/fulltext#section.0020)
37. Carter SA. Indirect Systolic Pressures and Pulse Waves in Arterial Occlusive Disease of the Lower Extremities. *Circulation*. 1968;37(4):624-637. <http://circ.ahajournals.org/content/37/4/624.full>
38. Yao ST, Hobbs JT, Irvine WT. Ankle systolic pressure measurements in arterial disease affecting the lower extremities. *British Journal of Surgery*. 1969;56(9):676-679. <https://onlinelibrary.wiley.com/doi/full/10.1002/bjs.1800560910>
39. Swaminathan A, Vemulapalli S, Patel MR, Jones WS. Lower extremity amputation in peripheral artery disease: Improving patient outcomes. *Vascular Health and Risk Management*. 2014;10:417-424. <https://www.ncbi.nlm.nih.gov/pmc/articles/PMC4107174/pdf/vhrm-10-417.pdf>
40. Morbach S, Furchert H, Gröblichhoff U, et al. Long-Term Prognosis of Diabetic Foot Patients and their Limbs: Amputation and death over the course of a decade. *Diabetes Care*. 2012;35(10):2021-2027. doi:10.2337/dc12-0200.
41. Caro J, Migliaccio-Walle K, Ishak KJ, Proskorovsky I. The morbidity and mortality following a diagnosis of peripheral arterial disease: Long-term follow-up of a large database. *BMC Cardiovascular Disorders*. 2005;5:14. <https://bmccardiovascdisord.biomedcentral.com/articles/10.1186/1471-2261-5-14>

## FACULTY, FAMILY MEDICINE RESIDENCY PROGRAM, RANCHO MIRAGE, CA

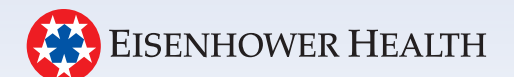

Become an integral part of an exciting young residency program that began in 2013. We have full 10-year ACGME accreditation. Eisenhower Health in Rancho Mirage, California seeks to hire an osteopathic (DO) faculty member to serve as part of our program effort to pursue Osteopathic Recognition. You will have outpatient care responsibilities and may choose to have inpatient care responsibilities. You will precept FM residents in the Center for Family Medicine. You have protected time for curriculum management, resident advising, and scholarly work.

Board certification in Family Medicine (ABMS or AOA) is required.

Eisenhower Health seeks candidates whose experience, teaching, research and community service have prepared them to contribute to our commitment to serving the Coachella Valley. Eisenhower is an EO/M employer. Qualified applicants, including recent residency graduates, are encouraged to apply.

Candidates should submit a digital CV and statement of interest to **Scott Nass, MD, MPA, Program Director** at [snass@eisenhowerhealth.org](mailto:snass@eisenhowerhealth.org) with cc: **Tamara Dunn** at [tdunn@eisenhowerhealth.org](mailto:tdunn@eisenhowerhealth.org). For questions, contact **Michelle Harding** at [mharding@eisenhowerhealth.org](mailto:mharding@eisenhowerhealth.org) or 760-773-4504.





# Curriculum on Developmental Disabilities in Family Medicine Residency

Bernadette Riley, DO, FACOFP, FILM

NYIT College of Osteopathic Medicine, Old Westbury, NY

## KEYWORDS:

Developmental Disabilities

Family Medicine Residencies

Medical Education

Single GME Accreditation System

ABSTRACT: Some Family Medicine residency training programs are going through changes since the Single Graduate Medical Education (GME) Accreditation System was implemented. In this time of exponential growth this is the time for incorporating curriculum on patients with developmental disabilities (DD) during family medicine residency. During the 2017 American Medical Association House of Delegates (AMA HOD) a resolution was passed calling for GME to begin a curriculum on treating children and adults with DD. During the 2018 AOA House of Delegates a resolution was approved as amended on implementing curriculum regarding the care of people with DD. This resolution along with new topics emerging in the field of developmental disability shows the need for training in family medicine residency programs. In order to meet the growing need of physicians trained in the care of patients with DD family medicine residency programs should implement a standardized curriculum on patients with DD. Family Medicine trainees will use the skills they learned during this curriculum in their practices, and will feel comfortable treating a patient with DD. Barriers exist for patients with DD to have appropriate access to healthcare, and the osteopathic family medicine community can help to limit these barriers. The time is now for the FM GME community to include a standardized curriculum for patients with DD.

## INTRODUCTION

According to the Center for Disease Control there are approximately one in six children in the United States living with developmental disabilities (DD).<sup>1</sup> Since the American Disability Act was passed in 1990, new laws have been put into place to expand opportunities for Americans living with all types of disabilities.<sup>2</sup> "Developmental disabilities are a group of conditions due to an impairment in physical, learning, language or behavior areas."<sup>3</sup> DD occurs before the age of 22, and last throughout one's life.<sup>4</sup> In the United States, the most common form of DD is an intellectual disability, followed by cerebral palsy and autism spectrum Disorders (ASD).<sup>4</sup> Most family medicine physicians in the US will encounter a patient with DD. Family physicians must realize that they need training in treating patients with DD. This training includes addressing the health disparities related to patients who have a DD.<sup>5</sup> Patients with DD have a shorter lifespan than the average population.<sup>5</sup> The Department of Health and Human Services launched "Healthy People 2020" to "improve the quality of life among individuals with disabilities of all ages."<sup>6</sup> Due to this increase in awareness,

the osteopathic family physician needs to be properly trained in treating and identifying patients with developmental disability. This training should continue to occur during the Family Medicine residency. With the Single GME Accreditation System culminating by July 2020, now is the time to ensure family medicine trainees are taught in recognizing and caring for patients with DD.

## WHY THE OSTEOPATHIC FAMILY MEDICINE COMMUNITY NEEDS TRAINING ON PATIENTS WITH DD

Since some developmental disabilities are increasing in frequency among the US population<sup>7</sup>, the osteopathic family physician needs to be educated in not only treating, but also identifying this population. In 2017, at the American Medical Associations' House of Delegates (AMA HOD), a resolution was passed that the "AMA recognize the importance of managing the health of children and adults with developmental disabilities as a part of overall patient care for the entire community."<sup>8</sup> The resolution further states

the "AMA encourage graduate medical education programs to develop and implement a curriculum on providing appropriate and comprehensive health care to people with DD."<sup>8</sup> In July 2018 the AOA House of Delegates (AOA HOD) approved resolution H-211 that states "that the AOA encourage osteopathic medical schools to develop and implement curricula on the care of people with developmental disabilities."<sup>9</sup> With the passage of resolutions by the AMA in 2017, the AOA in 2018, and the Single GME Accreditations System in place, it is imperative that the osteopathic community recognize the importance of training our residents on patients with DD. Osteopathic Family Medicine residents should be trained to recognize and properly treat patients with DD during their residency.

## NEED FOR TRAINING NOW

In a recent survey, the majority of medical and dental students surveyed "expressed inadequate competency in the care of [patients with DD]."<sup>10</sup> Drs. Holder, Waldman, and Hood showed in this study that medical and dental residency program directors "indicated a need for additional training for their residents."<sup>10</sup> This further shows the need for training in family medicine residency programs. The reason why this curriculum is imperative is that "persons with disabilities [are] an unrecognized health disparity population."<sup>11</sup> Often times the patient with a developmental disability interacts first with a family medicine physician before any other specialty. It is imperative that osteopathic family medicine residents are trained in properly identifying patients with DD.

## BARRIERS TO CARE FOR PATIENTS WITH DD

Children and adults with DD have more barriers to health care than others.<sup>12</sup> One barrier patients with DD have is a financial one, as patients with DD often have economic barriers, and may depend on governmental institutions or other sources of financial help for medical and/or living expenses.<sup>10</sup> There is also a stigma and prejudice associated with DD, and the health care provider can also have a stigma about patients with DD.<sup>10</sup> For clinicians who have not been trained in DD, many feel ill-prepared to deal with the patient with DD.<sup>10</sup> Through exposure to individuals with DD, the clinicians can see whether they show an "unconscious bias" to patients with DD.<sup>10</sup> This bias can be addressed, recognized and possibly remediated during family medicine training so that when the resident graduates they have a better understanding of caring for patients with DD. Many patients with DD have physical barriers to accessing care. These include walking devices, such as wheelchairs or auditory aides that may make it challenging for a patient with DD to get to the doctor.<sup>10</sup> Patients with DD can sometimes present communication challenges with their healthcare providers. Since "effective two-way communication is foundational to person-centered care" this can present an issue in the developmentally disabled population.<sup>12</sup> The family medicine resident can identify barriers to care that may be in place and learn to use a variety of methods to care for this population.

## HEALTHCARE PROFESSIONALS ALREADY UTILIZING A CURRICULUM ON PATIENTS WITH DD

Dental schools across the USA have realized the need of having a curriculum in patients with DD for over a decade. In 2004, The Commission on Dental Accreditation adopted standards to "prepare dental professionals for the care of persons with DD."<sup>13</sup> There are many secondary dental comorbidities seen in patients who have DD. The dental community has revised many standards, and education has been updated as the environment surrounding DD has changed. Dental schools have ensured that all US dental graduates are trained in dealing with patients who have DD.<sup>13</sup> Substantial research has been done in the dental community on patients with DD. The time is now for the osteopathic family physician to also ensure proper training in patients with DD.

## DIFFERENT STRATEGIES TO MEET DD CURRICULUM REQUIREMENTS

There are many ways that the dental community has tried to educate their dentists on patients with DD. One avenue dental professionals have used to educate learners is by incorporating simulation to teach the provider about DD.<sup>14</sup> This type of model can be used with a "flipped classroom" setting, where students are exposed to video or modules before their in-person face to face, or simulation.<sup>15</sup> This is beneficial as the learner can go at their own learning pace, and can prepare properly for their face to face teaching session with faculty. Research has shown that the "flipped classroom" method has been used to teach medical students regarding new developmental disability law and practice with good results.<sup>15</sup> This type of learning is a good way to engage family medicine residents in their training programs without using a lot of time and financial resources. The osteopathic family medicine community can start with a module using the flipped classroom as a way to ensure training in the field of developmental disability. Research from the dental community can help facilitate the family medicine training curriculum for residency programs.

Exposing family medicine residents to simulated scenarios involving children and adults with DD can help the trainees become comfortable taking care of the patient with DD. A study by Drs. Kleinert HL, Sanders C, Mink J, Nash D, Johnson J, Boyd S, Challman S showed dental students who were exposed to a "virtual patient module" of a developmentally disabled child felt satisfied and prepared for a real patient encounter.<sup>14</sup> "Educational encounters including personal encounters with patients, modeling by mentors, and reflective activities can foster qualities such as compassion and empathy."<sup>12</sup> Both of these qualities are imperative to the family physician, and for participating in the care of a child or adult with DD.

Some curriculum regarding DD incorporate simulation scenarios where "patients with disabilities [serve] as medical educators."<sup>16</sup> At Tufts University School of Medicine, "people with disabilities, in the role of "standardized" patients, portray patients with a common primary care complaint in simulated medical interviews."<sup>16</sup> This simulated learning environment can be especially promising for

## CORRESPONDENCE:

Bernadette Riley, DO, FACOFP, FILM | [briley@nyit.edu](mailto:briley@nyit.edu)

the osteopathic family medicine resident, where the resident can evaluate their encounter with a developmentally disabled patient.

Another avenue where family medicine residents can be taught about patients with DD is during a rotation. Clinical rotations and clinical clerkships can expose the trainee and student to patients with DD.<sup>17</sup> Graham et al. showed how exposing third-year medical students on their family medicine rotations to a 90-minute curriculum on patients with "mobility and cognitive impairments" helped the students' "knowledge and attitude" on the topic.<sup>18</sup>

## PATIENTS WITH DD AND LONG-TERM ISSUES

There are long-term issues that need to be addressed for a patient with DD. Formal standardized training should be incorporated into family medicine residency to address these long-term issues. A Canadian study by Dr. Sullivan et al. showed that treatment of a developmentally disabled patient involves "caregivers, adapting procedures when appropriate and seeking input from a range of health professionals."<sup>19</sup> This type of comprehensive care is seen every day in the continuity of care that family physicians encounter.

## OSTEOPATHIC MEDICAL COMMUNITY AND DIAGNOSIS OF DD

By incorporating curricula on DD in family medicine residency, the physician can identify a patient with a DD. This is especially important for identifying patients who would benefit from early intervention.<sup>20</sup> Since "one-half of American children with DD [are] not identified by the time they enter kindergarten" these patients lose valuable opportunities for early intervention strategies.<sup>20</sup> Osteopathic family physicians who conduct well visits and testing on specific developmental traits can identify a patient who has a developmental disability. Identifying these patients in early childhood would help the patient and caregiver find appropriate care and access appropriate services. Family medicine residents can also ask caregivers and parents to help access the need for early intervention.<sup>21</sup> By training our osteopathic Family Medicine residents in early intervention, this can potentially lead to greater recognition of patients with DD, and potential help and aide earlier in their diagnosis.

## CONCLUSION

With the passage of the AMA and AOA HOD resolutions encouraging implementation of a curriculum on patients with DD<sup>8, 9</sup> and the Single GME Accreditation System finalizing in 2020, now is the time to standardize the curriculum for family medicine residents on DD. The osteopathic family medicine community should recognize and encourage a model for identifying and treating patients with DD. By standardizing this curriculum and ensuring that Family Medicine resident get training in this population we can ensure appropriate care for the growing number of patients with DD. This curriculum can also help identify the disparity that exists in healthcare for patients with DD and can help address the need to break those barriers.

### AUTHOR DISCLOSURES:

No relevant financial affiliations

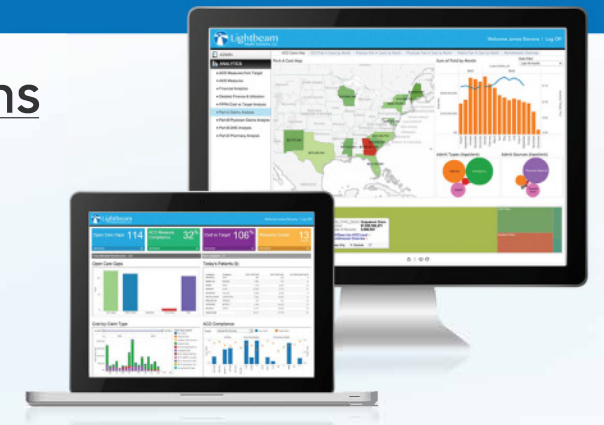### REFERENCES:

- Center for Disease Control and Prevention (CDC), Determining How Many People Have Developmental Disabilities- Tracking. <https://www.cdc.gov/ncbddd/developmentaldisabilities/about.html> Accessed July 9, 2018.
- CDC, Key Findings: Prevalence of Disability and Disability Type Among Adults, United States- 2013. <https://www.cdc.gov/ncbddd/disabilityandhealth/features/key-findings-community-prevalence.html> Accessed July 9, 2018.
- CDC, Facts about Developmental Disabilities. <https://www.cdc.gov/ncbddd/developmentaldisabilities/facts.html> Accessed July 9, 2018.
- May Institute- DD Q & A [www.mayinstitute.org](http://www.mayinstitute.org). [https://www.mayinstitute.org/pdfs/NEW%20pdfs/DD%20Q&A\\_rev4-10.pdf](https://www.mayinstitute.org/pdfs/NEW%20pdfs/DD%20Q&A_rev4-10.pdf) Accessed July 9, 2018.
- Lauer E, McCallion P. Mortality of People with Intellectual and Developmental Disabilities from Select US State Disability Service Systems and Medical Claims Data. *JARID* 2015;28 (5): 394-405. doi: [10.1111/jar.12191](https://doi.org/10.1111/jar.12191)
- Healthy People 2020. Disability and Health. <https://www.healthypeople.gov/2020/topics-objectives/topic/disability-and-health>. Assessed July 9, 2018.
- Boyle CA, Boulet S, Schieve LA, et al. Trends in the prevalence of developmental disabilities in US children, 1997-2008. *Pediatrics*. 2011 Jun;127(6):1034-42. doi: [10.1542/peds.2010-2989](https://doi.org/10.1542/peds.2010-2989). Epub 2011 May 23.
- American Medical Association House of Delegates Resolution: 315 A-17, 2017. <https://www.ama-assn.org/sites/default/files/media-browser/public/bot/a17-bot-reports.pdf> Accessed July 9, 2018.
- American Osteopathic Association 2018 House of Delegates Resolutions: Committee on Educational Affairs H-211. <https://osteopathic.org/wp-content/uploads/A2018-200-Series-WITHACTION.pdf> Accessed August 21, 2018.
- Holder M, Waldman B, Hood H. Preparing Health Professionals of Caring for Disabled Individuals. *International Journal of Oral Science*. 2009; 1(2): 66-71.
- Krahn GL, Walker DK, Correa-De-Araujo, R. Persons With Disability as an Unrecognized Health Disparity Population. *Am J Public Health*. 2015 Apr;105 Suppl 2: S198-206. doi: [10.2105/AJPH.2014.302182](https://doi.org/10.2105/AJPH.2014.302182). Epub 2015 Feb 17.
- Boyd, K. The Curriculum of Caring: Fostering Compassionate, Person-Centered Health Care. *AMA Journal of Ethics*. 2016 Apr; 18 (4): 384-392. doi: [10.1001/journalofethics.2016.18.4.medu1-1604](https://doi.org/10.1001/journalofethics.2016.18.4.medu1-1604).
- Waldman HB, Fenton SJ, Perlman SP, Cinotti DA. Preparing Dental Graduates to Provide Care to Individuals with Special Needs. *J Dent Educ*. 2005 Feb;69(2):249-54.
- Kleinert HL, Sanders C, Mink J, Nash D, Johnson J, Boyd S, Challman S. Improving student dentist competencies and perception of difficulty in delivering care to children with developmental disabilities using a virtual patient module. *J Dent Educ*. 2007 Feb;71(2):279-86.
- Sheppard ME, Vitalone-Raccaro N, Kaari JM, Ajumobi TT. Using a flipped classroom and the perspective of families to teach medical students about children with disabilities and special education. *Disabil Health J*. 2017 Oct;10(4):552-558. doi: [10.1016/j.dhjo.2017.03.012](https://doi.org/10.1016/j.dhjo.2017.03.012). Epub 2017 Mar 27.

- Minihan PM, Bradshaw YS, Long LM, et al. Teaching About Disability: Involving Patients with Disabilities as Medical Educators. *Disability Studies Quarterly* Fall 2004; 24 (4). DOI: <http://dx.doi.org/10.18061/dsq.v24i4.883>
- Havercamp SM, Navas Macho P. (2016) What Undergraduate and Graduate Students Should Know About Disability. In: Rubin I.L., Merrick J., Greydanus D.E., Patel D.R. (eds) *Health Care for People with Intellectual and Developmental Disabilities across the Lifespan*. Springer, Cham Springer Link 2125-2131. doi.org/10.1007/978-3-319-18096-0\_160
- Graham CL, Brown, RS, Zhen H, McDermott S. Teaching Medical Students About Disability in Family Medicine. *Fam Med*. 2009;41(8):542-441, 8, 542-544.
- Sullivan WF, Berg JM, Bradley E et al. Primary care of adults with developmental disabilities. *Can Fam Physician*. 2011 May; 57(5): 541-553.
- Mackrides P, Ryherd S. Screening for Developmental Delay. *Am Fam Physician*. 2011 Sep 1;84(5):544-9.
- Vitrikas K, Savard D, Bucay M. Developmental Delay: When and How to Screen. *Am Fam Physician*. 2017 Jul 1;96(1):36-43.

## Lightbeam Health Solutions

- Population Health Management
- Value-Based Care Guidance
- MIPS Quality Manager
- Proven Clinical & Financial Results



### Need Help With Your Quality Payment Program Strategy?

Lightbeam is for anyone who has to satisfy CMS Quality Payment Program requirements. Whether you're a solo practitioner, large hospital or ACO, Lightbeam enables you to manage complex patient populations easily and accurately in order to improve outcomes and reduce costs.

ACOFPP members will have access to the Lightbeam Platform at a reduced member price. For more information, email [advocacy@acofp.org](mailto:advocacy@acofp.org).

acofp AMERICAN COLLEGE OF OSTEOPATHIC FAMILY PHYSICIANS

Lightbeam Health Solutions



## CLINICAL IMAGE

## Eyelid Abnormalities in 76-Year-Old Male

Leonid Skorin, Jr., DO, OD, MS<sup>1</sup>; Marisa Asheim, BS<sup>2</sup>

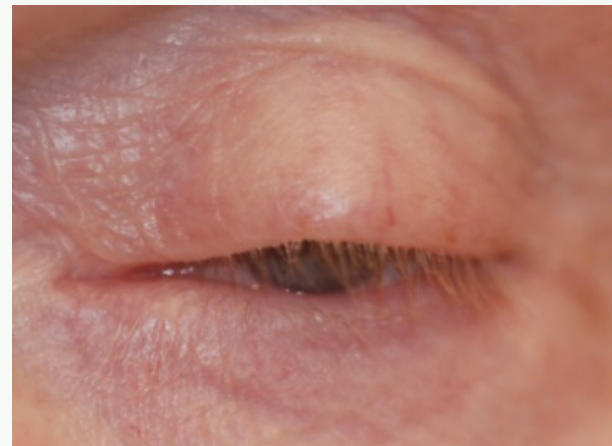<sup>1</sup> Mayo Clinic Health System, Albert Lea, MN

<sup>2</sup> Pacific University College of Optometry, Forest Grove, OR

A 76-year-old male presents with complaints of frequent eyelid and eye infections. He notes constant dry, yet watering eyes and matting of his eyelashes. He has no history of eyelid surgery or trauma and denies any past history of facial weakness. On physical examination, the patient could not fully close his eyes with normal blinking (*Figure 1*). In addition, there was an outward turning of the lower eyelids leading to excess tearing. He was placed on a dry eye treatment regimen of lid scrubs, lubricating artificial tears and ointment, warm compresses and lid taping at bedtime. This brought some relief to the patient's symptoms; but, he still was not completely satisfied.

**FIGURE 1:**

The patient was instructed to gently close his eyes. Incomplete eyelid closure is seen.



### QUESTIONS

#### 1. Based on Figure 1, what is the diagnosis?

- A. Lagophthalmos
- B. Exophthalmos
- C. Myasthenia Gravis
- D. Orbital fat prolapse
- E. Bell palsy

#### 2. Based on the finding of outward turning lower eyelids, what is the diagnosis?

- A. Ptosis
- B. Ectropion
- C. Entropion
- D. Blepharitis
- E. Dermatochalasis

#### 3. What is the most common etiology of the condition in Question 2?

- A. Congenital
- B. Paralytic
- C. Involutional
- D. Cicatricial
- E. Mechanical

### CORRESPONDENCE:

Leonid Skorin, Jr., DO, OD, MS | [skorin.leonid@mayo.edu](mailto:skorin.leonid@mayo.edu)

### ANSWERS:

#### 1. Based on Figure 1, what is the diagnosis?

Correct Answer: A) Lagophthalmos

Lagophthalmos is the inability to close the eyes completely and is caused by a variety of conditions<sup>1</sup>. Exophthalmos, or an excessively protruding eye, can cause an inability to close the eyes but will show a more prominent globe with visible sclera.<sup>2</sup> Myasthenia gravis will cause ptosis and progressive weakening of the upper eyelid throughout the day but does not always result in an inability to close the eyelids completely.<sup>3</sup> Orbital fat prolapse, a benign finding related to aging, will present with a prominent yellow-white elevated mass under the conjunctiva<sup>4</sup> Although Bell palsy will cause lagophthalmos, this patient denied a history of facial weakness, so the condition was ruled out.<sup>5</sup>

#### 2. Based on the finding of outward turning lower eyelids, what is the diagnosis?

Correct Answer: B) Ectropion

Ectropion is the outward turning of the eyelid margin, as shown in *Figure 3*. Entropion is characterized by the opposite finding, an inward turning of the eyelid.<sup>6</sup> Blepharitis is an inflammation of the eyelids that results in red, irritated eyes. Patients with blepharitis will experience crusting, flaking, eyelids sticking together and often complain of gritty, burning, greasy and itchy sensations.<sup>7</sup> Ptosis is the weakening of the levator muscle which causes drooping of the upper eyelid.<sup>8</sup>

#### 3. What is the most common etiology of the condition in Question 2?

Correct Answer: C) Involutional

Ectropion is most commonly involutional (age-related) and caused by relaxation of tissue that leads to eyelid laxity and punctal eversion.<sup>6</sup> Paralytic ectropion is often due to 7th nerve palsy and is usually temporary.<sup>1</sup> Congenital ectropion is rare and usually associated with Down syndrome or ichthyosis.<sup>8</sup> Cicatricial ectropion can be caused by trauma, chemical burns, surgery or scarring.<sup>1</sup> Eyelid tumors, herniated orbital fat, conjunctival chemosis or other anatomical abnormalities can lead to mechanical ectropion.<sup>1</sup>

### DISCUSSION

Although lagophthalmos is commonly caused by thyroid ophthalmopathy, in this patient it was secondary to ectropion. Lagophthalmos can also be caused by scarring, tumor, Bell palsy or after blepharoplasty and ptosis lid repair. The incidence of lagophthalmos increases with age and occurs more frequently in females. An estimated 5% of the normal population has lagophthalmos but many consider it to be a commonly underdiagnosed condition. This condition may show staining of the inferior corneal surface and eye irritation that is worse in the morning.<sup>9</sup> This staining is known as exposure keratopathy when the

inferior corneal surface dries and breaks down while the patient is sleeping.<sup>10</sup>

Ectropion in adults is most commonly age-related; more rarely, the condition may be paralytic, cicatricial, inflammatory or mechanical. Involutional ectropion is the result of eyelid tissue relaxation and horizontal lid laxity and presents with eversion of the lower eyelid and punctum.<sup>11,12</sup>

Involutional ectropion is a progressive condition, so there may be no initial symptoms or mild complaints of dry or watering eyes. In more advanced stages, foreign body sensation, mucus discharge, pain, or even decreased vision may be noted.<sup>11</sup>

One of the first signs of involutional lower lid ectropion is punctal eversion which prevents tears from draining properly and can lead to epiphora.<sup>12</sup> As the condition worsens and the lower eyelid begins to droop more, exposure of the cornea may occur. This will present as superficial punctate keratitis of the cornea and, in severe cases, ulceration. With chronic exposure, the eyelid can become inflamed and result in redness, keratinization of the conjunctiva and thickening of the tarsal plate. Chronic damage to the surface of the eye and eyelids makes patients susceptible to infection and more inflammation, leading to progression of the ectropion.<sup>12</sup>

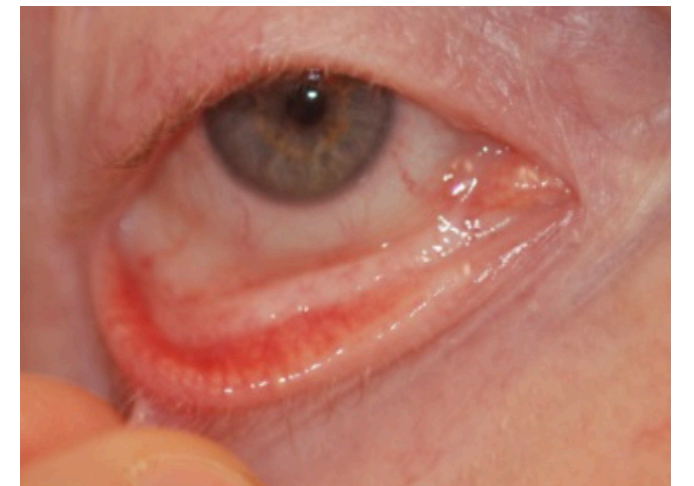
### EVALUATION

Prompt identification and initiation of treatment by the patient's family physician can greatly improve the quality of life of these patients. The following tests are useful in determining the presence and degree of involutional ectropion.

**Distraction test:** Pull the lower lid away from the globe and note the maximum displacement of the eyelid margin. If the distance is >10 mm, ectropion is present (*Figure 2*).<sup>11,12</sup>

**FIGURE 2:**

Distraction test showing >10 mm displacement of the eyelid margin from the globe in our patient.



**Snap back test:** Performed by pulling the lower lid down 8-10 mm and releasing it, then evaluating the return position of the lid. A normal lid should immediately return to position against the globe. The test is graded based on the position of the lid after release (Figure 3).<sup>13</sup>

**Grade 0:** normal eyelid, snaps back immediately on release

**Grade I:** 2-3 seconds before positioning against the globe

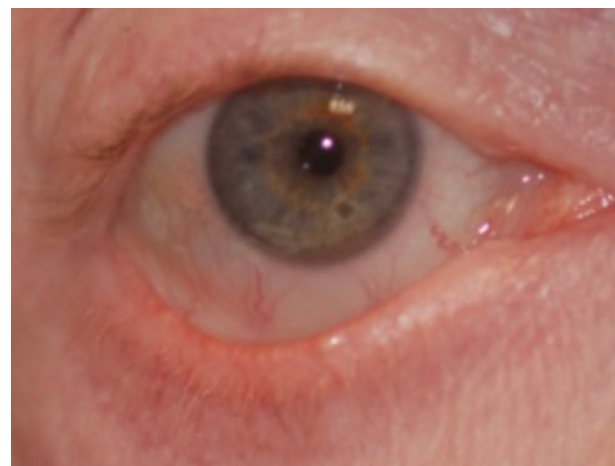
**Grade II:** 4-5 seconds before positioning against the globe

**Grade III:** >5 seconds but returns to position with blink

**Grade IV:** does not return to position and continues to rest away from the globe even after blink.

#### FIGURE 3:

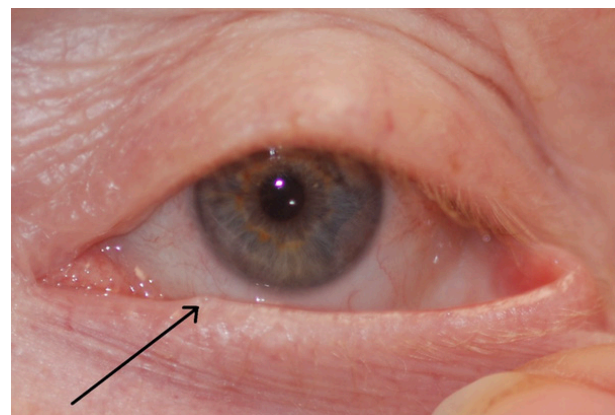
Everted eyelid during the snap-back test, Grade III. Positions itself against the globe only after a blink.



**Medial canthal tendon laxity:** Pull the lid temporally and observe the lateral movement of the inferior punctum. Lateral movement of 1-2mm is considered normal, the punctum displaced to the limbus of the globe indicates mild laxity, and, if severe, it will be displaced to the margin of the pupil (Figure 4).<sup>6</sup>

#### FIGURE 4:

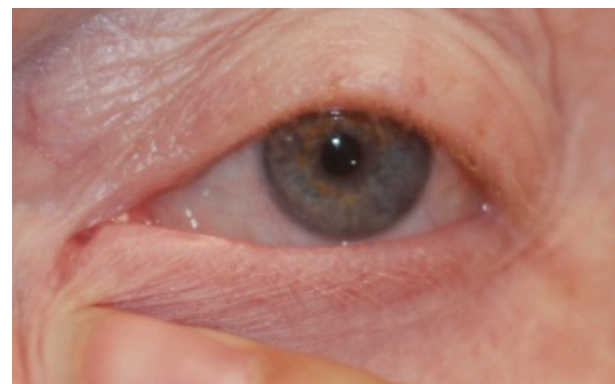
Medial canthal tendon laxity test showing punctal displacement to the limbus (arrow is showing position of the punctum).



**Lateral canthal tendon laxity:** An abnormal lateral canthus may have a more rounded appearance and can be displaced medially more than 2mm (Figure 5).<sup>6</sup>

#### FIGURE 5:

Lateral canthal tendon laxity test showing >2mm displacement.



**Lagophthalmos:** Have the patient gently close their eyes, as if they are sleeping. If the eyelids don't touch completely or the inferior part of the eye is visible, the eyelids should be taped at night to prevent ocular surface damage (Figure 1).

## TREATMENT

Conservative treatment should be attempted before corrective surgery is performed. Reducing corneal and conjunctival exposure is the primary concern, so artificial tears, gels and ointments may be administered throughout the day and before bed (Table 1 shown on page 35). At bedtime, the eyelids may be taped shut to prevent nocturnal lagophthalmos. The patient should be reminded not to rub their eyes which can exacerbate the problem. When conservative treatment is no longer sufficient, referral to an ophthalmologist or oculoplastic specialist for eyelid surgery should be considered.

#### AUTHOR DISCLOSURE:

No relevant financial affiliations

#### REFERENCES:

1. Bagheri N., Wajda B. N., Calvo C. M., Durrani A. K., Friedberg M. A., Rapuano C. J. (Eds.). (2017). In *The Wills Eye Manual: Office and emergency room diagnosis and treatment of eye disease* (7th Edition pp. 1-4, 130-146). Philadelphia, PA: Lippincott Williams & Wilkins.
2. Pass, A. F. (2011). Exophthalmometry. In Onofrey B. E., Skorin L., Holdeman N. R. (Eds.). *Ocular Therapeutics Handbook: A Clinical Manual* (3rd Edition, pp. 69-70). Philadelphia, PA: Lippincott Williams & Wilkins.

TABLE 1:

TRADE NAME	MANUFACTURER	MAJOR COMPONENT	PRESERVATIVE
<b>Lubricating Drops/Gels</b>			
Blink Tears	AMO	Polyethylene glycol, hyaluronic acid	OcuPure
Clear Eyes Pure Relief for Dry Eyes	Prestige	Glycerin	Preservative free, multi-dose bottle
Refresh Optive Gel	Allergan	CMC*, glycerin	Purite
Refresh Plus	Allergan	CMC*	None
Soothe XP	Bausch & Lomb	Restoryl, mineral oil	Polyhexamethylene biguanide
Soothe Preservative Free	Bausch & Lomb	Glycerin	None
Systane	Alcon	Polyethylene glycol, propylene glycol	Polyquaternium-1
Thera Tears	Advanced Vision Research	CMC*	Perbonate
<b>Lubricating Ointment</b>			
Advanced Eye Relief Night Time	Bausch & Lomb	White petrolatum, mineral oil	None
GenTeal PM	Novartis	White petrolatum, mineral oil	None
Refresh PM	Allergan	White petrolatum, mineral oil, lanolin	None
Systane Nighttime	Alcon	White petrolatum, mineral oil	None

\*CMC: carboxymethylcellulose

Note: this is not an exhaustive list of all available over-the-counter products

3. Skorin L., Muchnick B. G. (2011). Myasthenia Gravis. In Onofrey B. E., Skorin L., Holdeman N. R. (Eds.). *Ocular Therapeutics Handbook: A Clinical Manual* (3rd Edition, pp. 571-573). Philadelphia, PA: Lippincott Williams & Wilkins.
4. Skorin L. (2014). Diagnosis and excision of subconjunctival herniation of orbital fat. *Optometry and Visual Science*. 91:e236-e240. Doi: 10.1097/OPX.0000000000000342.
5. Skorin L. (2011). Facial Nerve Palsy. In Onofrey B. E., Skorin L., Holdeman N. R. (Eds.). *Ocular Therapeutics Handbook: A Clinical Manual* (3rd Edition, pp. 553-555). Philadelphia, PA: Lippincott Williams & Wilkins.
6. Bowling B., Kanski J. J. (2016). Eyelids. *Kanski's Clinical Ophthalmology*. (8th Edition, pp. 38-51). Philadelphia, PA: Elsevier.
7. Mayo Clinic. (2018, April 21). Blepharitis. Retrieved June 18, 2018, from <https://www.mayoclinic.org/diseases-conditions/blepharitis/diagnosis-treatment/drc-20370148>.
8. Corredor-Osorio R., Tovilla-Pomar J.L., Tovilla-Canales J.L. (2017). Congenital upper eyelids ectropion in Down's syndrome. *GMS Ophthalmology Cases*, 7, Doc 03. doi:10.3205/oc000054
9. Gum K. B. (2016). Clinical Anatomy of the Eye. In Gault J.A., Vander J. F. (Eds.). *Ophthalmology Secrets in Color*. (4th Edition, pp. 1-6). Philadelphia, PA: Elsevier.
10. Nesi F. A., Gladstone G. J., Brazzo B. G., Myint S., Black E. H. (2001) Classification and Treatment of Eyelid Malposition. *Ophthalmic and Facial Plastic Surgery*. (pp. 83-109). Thorofare, NJ: Slack Inc.
11. Gladstone G. J. (2011). Ectropion. In Onofrey B. E., Skorin L., Holdeman N. R. (Eds.). *Ocular Therapeutics Handbook: A Clinical Manual* (3rd Edition, pp. 602-605). Philadelphia, PA: Lippincott Williams & Wilkins.
12. Robinson F. O., Collin R. O. (2014). Ectropion. In Yanoff M., Duker J. S. (Eds.). *Ophthalmology*. (4th Edition, pp. 1284-1291). Philadelphia, PA: Elsevier.
13. Bashour M. (2015, December 22). Lower Lid Ectropion Blepharoplasty Workup. Medscape. Retrieved June 22, 2018, from <https://emedicine.medscape.com/article/1281565-workup>



## CALENDAR OF EVENTS

### JUNE 7 - 9, 2019

Maine ACOFP - Annual Oceanside Convention  
Samoset Resort, Rockport, Maine

### JUNE 27 - 29, 2019

Direct Primary Care Summit  
Hyatt Regency O'Hare, Rosemont, Illinois

### JULY 31 - AUGUST 4, 2019

Florida ACOFP  
Omni Champions Gate Resort, Orlando, Florida  
[www.fsacofp.org](http://www.fsacofp.org)

### JULY 31 - AUGUST 4, 2019

ACOFPCA43 CME Seminar  
Anaheim, California  
[www.acofpca.org](http://www.acofpca.org)

### AUGUST 8 - 11, 2019

Michigan ACOFP Summer Family Medicine Update  
Park Place Hotel, Traverse City, Michigan  
[www.maofp.org](http://www.maofp.org)

### AUGUST 9 - 11, 2019

Annual POFPS CME SYMPOSIUM  
Hershey Lodge, Hershey, Pennsylvania  
[www.poma.org](http://www.poma.org)

### OCTOBER 25 - 28, 2019

OMED  
Baltimore, Maryland  
[www.poma.org](http://www.poma.org)

### CME Resource: Osteopathic Family Physician Offers 2 Hours of 1-B CME

ACOFPC members who read Osteopathic Family Physician can receive two hours of Category 1-B continuing medical education credit for completing quizzes in the journal. Visit the eLearning Center at [www.acofp.org](http://www.acofp.org) to access the quizzes.

**OFP**  
Osteopathic Family Physician

## 2018 ATTENDING PAPER OF THE YEAR AWARD

"Current Concepts in the Office-Based Treatment of Concussed Athletes"

*Presented to*



Robert Franks, DO, FAOASM



Danielle Chase, PhD



Ronald Torrance II, DO

## 2018 RESIDENT PAPER OF THE YEAR AWARD

"Approach to Polyarthritis for the Primary Care Physician"

*Presented to*




Arielle Freilich, DO

## 2018 STUDENT AUTHOR OF THE YEAR AWARD

"Abnormal Uterine Bleeding: An Age Based Approach"

*Presented to*

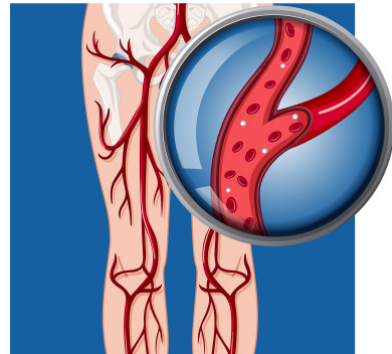


Heather Johnston, OMS

## PERIPHERAL ARTERY DISEASE: KNOW YOUR RISK FACTORS

Meenal Balakrishnan, OMS, JD

Ronald Januchowski, DO, FACFP, Editor • Paula Gregory, DO, MBA, CHCQM, FAIHQ, Health Literacy Editor



Peripheral Artery Disease (PAD) is caused by plaque build-up in the arteries bringing blood to your arms, legs, organs, and brain. The plaque is formed by cholesterol, fat, calcium, fibrous tissue, and other blood products. After damage to your arteries, the body begins to heal and the healing may cause plaque to form at the site of damage. The plaque hardens and narrows arteries. The plaque can also break off, further damaging the arteries and causing a blood clot to form at the site. Plaque or blood clots can limit the flow of oxygenated blood through the arteries to tissues. PAD can cause a variety of issues ranging from pain to skin changes.

### WHAT ARE MY PAD RISK FACTORS?

The American College of Cardiology/American Heart Association (ACC/AHA) identified certain groups with an increased risk such as:

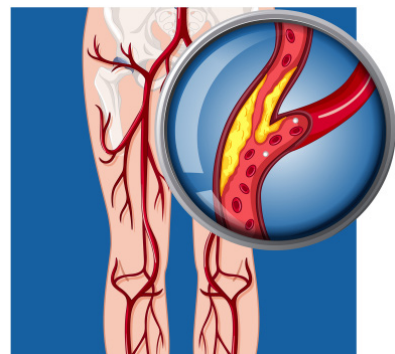
- Over 70 years
- Age 50 to 69 years with a history of smoking or diabetes
- Age 40 to 49 with diabetes and at least one other risk factor for atherosclerosis, including:
  - Male gender
  - Black ethnicity
  - Family history of atherosclerosis
  - Smoking
  - High cholesterol
  - High blood pressure
  - Homocysteinemia
- Abnormal lower extremity pulse examination
- Known atherosclerosis

### HOW PAD IS DIAGNOSED

- If PAD is suspected, your doctor can diagnose PAD by comparing the blood pressures of a patient's ankles and arms and running different neurological and blood tests.

### HOW TO PREVENT PAD

No organization currently recommends routine screening for PAD in a patient with NO symptoms, the USPSTF does recommend ways to reduce risk. The best way to avoid PAD is to limit the amount of arterial damage. This includes smoking cessation, a heart-healthy diet, medications, and blood pressure control.



SOURCE(S): UpToDate; U.S. Department of Health and Human Services; Medscape

The *Osteopathic Family Physician* Patient Handout is a public service of the ACOFP. The information and recommendations appearing on this page are appropriate in many instances; however, they are not a substitute for medical diagnosis by a physician. For specific information concerning your medical condition, ACOFP suggests that you consult your family physician. This page may be photocopied noncommercially by physicians and other healthcare professionals to share with their patients.

For additional patient related educational material please visit our website at [www.acofp.org](http://www.acofp.org).

# EVERYBODY KNOWS YOUR NAME



## WHERE HEALTH IS PRIMARY.

 **Health is  
Primary**  
BROUGHT TO YOU BY AMERICA'S FAMILY PHYSICIANS

Long-term relationships between doctors and patients build trust and lead to better outcomes.

Family doctors work with their patients throughout their lives. We want to give all patients access to this kind of continuing care.

Let's make health primary in America.  
Learn more at [healthisprimary.org](http://healthisprimary.org).

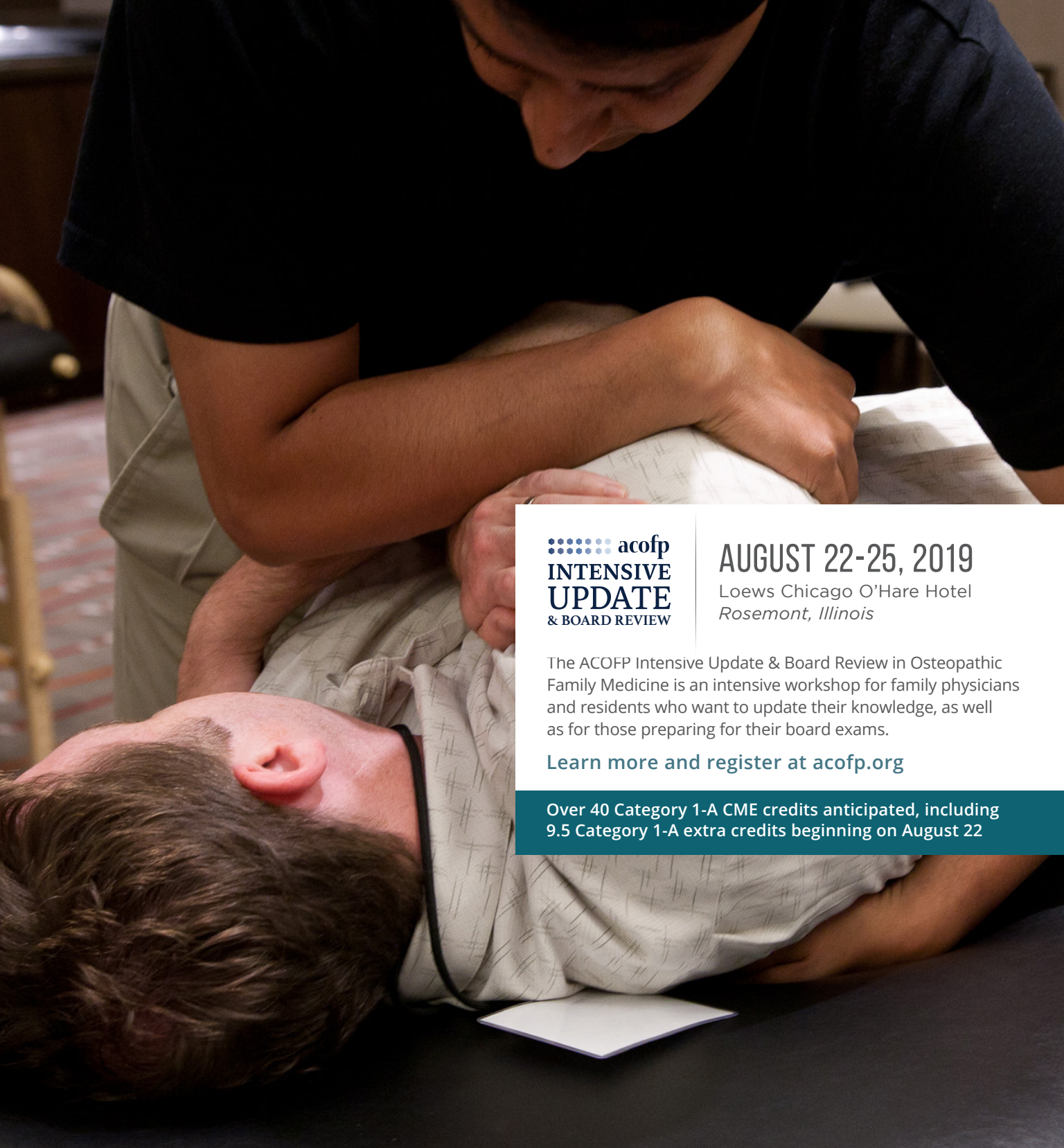 **HealthIsPrimary**

**#MakeHealthPrimary**



American College of Osteopathic Family Physicians  
330 East Algonquin Road, Suite 1  
Arlington Heights, IL 60005

Non-Profit Org.  
U.S. Postage  
**PAID**  
Carol Stream, IL  
PERMIT NO.  
1746



 **acofp**  
**INTENSIVE**  
**UPDATE**  
& BOARD REVIEW

**AUGUST 22-25, 2019**

Loews Chicago O'Hare Hotel  
*Rosemont, Illinois*

The ACOFP Intensive Update & Board Review in Osteopathic Family Medicine is an intensive workshop for family physicians and residents who want to update their knowledge, as well as for those preparing for their board exams.

**Learn more and register at [acofp.org](http://acofp.org)**

**Over 40 Category 1-A CME credits anticipated, including 9.5 Category 1-A extra credits beginning on August 22**