

CLINICAL IMAGE

INTRANASAL MANIFESTATION OF GRANULOMATOUS DISEASE IN COMMON VARIABLE IMMUNODEFICIENCY

Marija Rowane, OMS-III¹; David McGarry, DO²; Robert Hostoffer, DO, LhD, MSMEd, FAAP, FACOP, FACOI, FCCP³

¹ Ohio University Heritage College of Osteopathic Medicine, Athens, OH

²Spokane Allergy & Asthma Clinic, Spokane, WA

³Department of Pulmonary & Critical Care, University Hospitals Cleveland Medical Center, Cleveland, OH

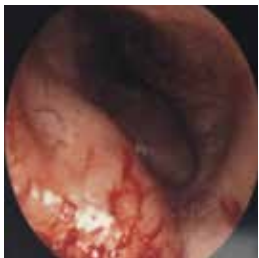INTRODUCTION

A 26-year-old female presents to the allergy/immunology office with recurrent epistaxis, mild shortness of breath on exertion and nasal congestion. Her past medical history is significant for allergic rhinitis, asthma, osteopenia and hypogammaglobulinemia that is managed with monthly intravenous immunoglobulin (IVIg) replacement. Her initial serum Ig tests had revealed 469 mg IgG/dL (608-1229 mg/dL) and 59 mg IgA/dL (81-463 mg/dL), in addition to minimal response to childhood vaccination.

The patient reports intermittent, one to two-hour episodes of epistaxis about two to three times per day. She denies fevers, chills, headaches, hematuria, hematochezia and bruising. Physical examination and nasal endoscopy convey an obstructive mass in the left nasal passage. (Figure 1) A complete blood cell (CBC) panel denotes normocytic anemia with 10.7 g/dL hemoglobin (11.5-15.5 g/dL) and 31% hematocrit (35-45%). Prothrombin time and International Normalized Ratio were within normal limits. A computed tomography (CT) scan without contrast showed an obstruction of the left nasal passage with a soft tissue mass. (Figure 2) The intranasal granuloma was surgically resected. (Figure 3) Pathologic gross and microscopic evaluation revealed an intranasal granuloma. (Figure 4)

FIGURE 1:

Nasal endoscopy image of the granuloma within the naris



CORRESPONDENCE:

David McGarry, DO | davemcgarry1@gmail.com

FIGURE 2:

Computed tomography scan demonstrating intranasal granuloma

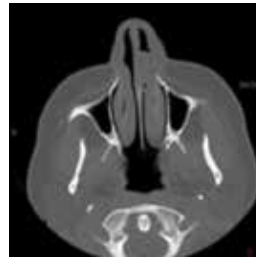

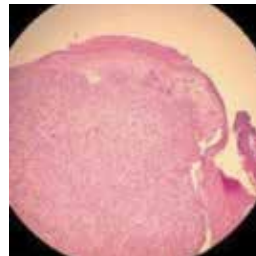
FIGURE 3:

Post-surgical specimen of intranasal granuloma

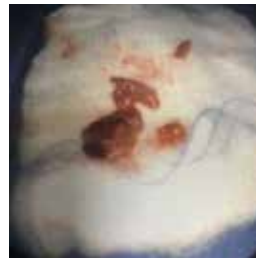

FIGURE 4:

Histology showing intranasal granuloma



QUESTIONS:**1. What do the nasal endoscopy and computed tomography scan reveal?**

- A. Nasal polyp
- B. Intranasal granuloma
- C. Squamous cell carcinoma
- D. Turbinate hypertrophy

2. What is the underlying etiology?

- A. Chronic allergic rhinitis
- B. Chronic rhinosinusitis with nasal polyposis
- C. Common variable immunodeficiency
- D. Cystic fibrosis

ANSWERS:**1. What do the nasal endoscopy and computed tomography scan reveal?****Correct Answer:***B) Intranasal granuloma*

Nasal pathophysiologic changes may be among early manifestations of systemic diseases and involve recurrent or severe epistaxis, mucosal pathologic processes and involvement of a symptom complex.¹ Macroscopic and microscopic evaluation and radiographic images guide differentiation between the neoplastic and non-neoplastic lesions that may arise in these systemic diseases.² Nasal granulomas are noncaseating, tight masses of epithelioid cells, surrounded by lymphocytes and fibroblasts.¹ Multinucleated giant cells that constitute granulomas may develop up to 150 µm in diameter, in response to infection or inflammation.¹ Although nasal polyps are the most common non-neoplastic cause of nasal obstruction,² they are distinguished from the current case by their locality in the middle meatus, hyperdense and heterogeneous opacification and presence of anatomic variations, such as a hypertrophied uncinat process or septal deviation.³ Squamous cell carcinoma is the most common malignant nasopharyngeal mass with differentiation in the form of intracellular keratin, intercellular bridges and extracellular keratin pearls.² Cellular hyperplasia, tissue oedema, vascular congestion and bony enlargement characterize the nonspecific classification of turbinate hypertrophy.

2. What is the underlying etiology?**Correct Answer:***C) Common variable immunodeficiency*

Allergic rhinitis involves inflammation of nasal tissue, obstructing sinuses with the progression of mucosal membrane swelling and congestion to bacterial infection, neutrophil influx and inflammation.³ The more extensive abnormalities on sinus CT images of chronic rhinosinusitis with nasal polyposis predominantly present with hyposmia or anosmia and nasal congestion.³ Other vague symptoms may include headache,

halitosis, fatigue, dental pain, cough, throat clearing and/or ear pain.³ These symptoms will have persisted for at least 12 weeks and may demonstrate sclerosis of the sinus walls on CT.³ Cystic fibrosis (CF) will most often convey underdeveloped sinuses, especially the frontal sinus.¹ Patients with CF may present with grayish-green phlegm indicative of bacterial infection, likely *Pseudomonas aeruginosa* or *Staphylococcus aureus*.¹ Although nasal granulomas have not been reported in patients with Common Variable Immunodeficiency (CVID), between 8% and 22% present with granulomatous infiltration in one or more organ system.⁵

DISCUSSION

Common variable immunodeficiency (CVID) is a nonspecific primary immunodeficiency (PID) with a prevalence of 1:30,000 patients.⁵ Diagnostic criteria for CVID are controversial but often include age over four years of age, hypogammaglobulinemia, defective antibody responses, recurrent infections and exclusion of other primary and secondary immunodeficiencies.⁵⁻⁶ The undetermined etiology of CVID may involve diminished B cell, T-cell, cytokine and dendritic cell function, as well as gene mutations, such as the inducible co-stimulator (ICOS), Cluster of Differentiation (CD) 19 or TNFRSF13B gene encoding Transmembrane activator and calcium modulator and cyclophilin ligand interactor (TACI).⁶ Standard management includes antimicrobials, immunoglobulin replacement and monitoring of pulmonary status.⁵ Although relatively common, granulomatous tissue involvement often propagate misdiagnosis of sarcoidosis or delayed diagnosis and, thus, appropriate treatment.⁷

Granulomas are clusters of caseating or noncaseating tissue that primarily manifest in lungs, lymph nodes, liver, spleen or skin.⁷ Inflammatory cytokines stimulate macrophage fusion into multinucleated giant cells that manifest as granulomatous reactions in inflammatory diseases, such as sarcoidosis, Crohn's disease, rheumatoid arthritis and CVID.⁸ The CVID granulomatous process is grossly similar to that of sarcoidosis but is distinguished by its epidemiology.⁷ Evidence suggests that patients with the most impaired T-cell immunity, fewest switched memory B cells and/or unusual tumor necrosis factor (TNF) polymorphisms may foster a cytokine environment more susceptible to granuloma formation.⁷⁻⁸ This uncertain pathophysiology may require additional or alternative therapies to high-dose IVIG and/or corticosteroids, such as surgical excision required to reduce the severe nasal obstruction in the present case).^{1,7-8}(Figure 3)

Granulomatous disease in CVID has been associated with polyclonal lymphocytic inflammation, presenting as lymphocytic interstitial pneumonia and persistent lymphadenopathy that evolves into granulomatous-lymphocytic interstitial lung disease (GLILD).⁹ Excessive lymphoproliferation instigates the development of granulomas and their subsequent pervasion to other organs.⁹ Ardeniz and Cunningham-Rundles documented granulomas in one or more organs of 37 (8.1%) out of 455 patients with CVID.⁶ In addition to lung granulomas in 20 (54%) patients, other localities, in order of increasing prevalence, included lymph nodes, liver, skin, spleen, bone marrow, brain, retina, small bowel and kidney.⁶ A meta-analysis by Song et al. revealed noncaseating granulomatous manifestations in 8% to 22% of patients with

CVID.¹⁰ Scott-Taylor *et al.* diagnosed granulomatous liver disease in five out of 24 patients with CVID.⁹ The latest reported granuloma was localized at a subcutaneous IVIG site in a CVID patient.¹¹ The literature is limited with few documentations of granulomas in CVID and no existing findings of nasal granulomas in this PID.⁵⁻¹² We report the first case of an intranasal granuloma in a patient with CVID.

CONCLUSION

CVID is a relatively common form of PID of complex etiology and variable clinical manifestations.⁵ Granulomatous lesions, such as GLILD and granulomatous liver disease, are common complications in patients with CVID but have not been identified in the nasal passage.⁵⁻¹² We offer the first report of an intranasal granuloma in a patient with CVID. The diagnostic images and information may guide future differential diagnoses of granulomatous manifestations in inflammatory diseases.

AUTHOR DISCLOSURE(S):

The author(s) declare no relevant financial affiliations or conflicts of interest.

REFERENCES:

- McCaffrey TV. Nasal manifestations of systemic diseases. *Otolaryngol Pol.* 2009;63(3):228-35. doi:10.1016/S0030-6657(09)70113-1.
- Garg D and Mathur K. Clinico-pathological Study of Space Occupying Lesions of Nasal Cavity, Paranasal Sinuses and Nasopharynx. *JCDR.* 2014;8(11):FC04-07. doi:10.7860/JCDR/2014/10662.5150.
- Peters AT, Spector S, Hsu J, et al. Diagnosis and management of rhinosinusitis: a practice parameter update. *Ann Allergy Asthma Immunol.* 2014;113:347-85. doi:10.1016/j.anai.2014.07.025.
- Farmer SEJ and Eccles R. Chronic inferior turbinate enlargement and the implications for surgical intervention. *Rhinology.* 2006;44:234-238. https://www.rhinologyjournal.com/Rhinology_issues/588.pdf
- Bonilla FA, Khan DA, Ballas ZK, Chinen J, Frank MM, Hsu JT. Practice parameter for the diagnosis and management of primary immunodeficiency. *J Allergy Clin Immunol.* 2015;136(5):1186-1206.e78. doi:10.1016/j.jaci.2015.04.049.
- Ardeniz O and Cunningham-Rundles C. Granulomatous Disease in Common Variable Immunodeficiency. *Clin Immunol.* 2009;133(2):198-207. doi:10.1016/j.clim.2009.05.001.
- Cunningham-Rundles C, Routes JM, Hostoffer R, Sullivan KE. Uncommon conundrum in common variable immunodeficiency. *Clin Immunol.* 2005;116:208-10. doi:10.1016/j.clim.2005.04.006.
- Scott-Taylor TH, Whiting K, Pettengell R, Webster DA. Enhanced formation of giant cells in common variable immunodeficiency: Relation to granulomatous disease. *Clin Immunol.* 2017;175:1-9. doi.org/10.1016/j.clim.2016.11.002.
- Maglione PJ. Autoimmune and Lymphoproliferative Complications of Common Variable Immunodeficiency. *Curr Allergy Asthma Rep.* 2016;16(19):1-10. doi:10.1007/s11882-016-0597-6.
- Song J, Lleo A, Yang GX, et al. Common Variable Immunodeficiency and Liver Involvement. *Clinic Rev Allerg Immunol.* 2018;55:340-35. doi:10.1007/s12016-017-8638-z.
- Gupta A, Wang B, Gupta S. Granuloma-like lesion at subcutaneous immunoglobulin site in a common variable immunodeficiency patient. *Immunotherapy.* 2019;11(14). doi:10.2217/imt-2019-0109.
- Prasse A, Kayser G, Warnatz K. Common variable immunodeficiency-associated granulomatous and interstitial lung disease. *Curr Opin Pulm Med.* 2013;19(5):503-09. doi:10.1097/MCP.0b013e3283642c47.