



Update on diagnosis, treatment, and prevention of genital human papillomavirus manifestations

Robin Quesenberry Olsen, MD, MPH, MS, Laura B. Cieraszynski, DO,
Shannon M. Bishop

From the Department of Family Medicine/Medical Education, Virginia Tech-Carilion SOM Family Medicine Residency, Roanoke, VA.

KEYWORDS:

Human
papillomavirus;
Oncogenic HPV;
Genital warts;
Gardasil;
Cervarix;
Dysplasia;
Neoplasia

Human papillomavirus (HPV) affects 20 million people across the globe each year. The prevalence of HPV is vast. The Centers for Disease Control and Prevention report that at least 50% of all sexually active men and women will contract HPV at some point in their lives. The most drastic and consequential effect of HPV in a carrier is the risk of developing cancer. Cervical cancer is the most commonly reported anogenital cancer; however HPV can cause other cancers, such as vulvar, vaginal, penile, and anal. In addition to cancer, nononcogenic HPV strains cause visible warts, specifically HPV types 6 and 11. There are more than 100 strains of HPV, approximately 30 of which affect the genital tract. Based on the risk of cancerous potential, genital tract HPV strains are divided into low risk (nononcogenic) and high-risk (oncogenic) subtypes. Although visible warts do not have the same cancerous potential, they cause distress through embarrassment, as well as create uncomfortable symptoms including itching, burning, and localized bleeding. This review article will address the diagnosis, treatment, and prevention of anogenital HPV manifestations, both from low- and high-risk subtypes.

© 2011 Published by Elsevier Inc.

Human papillomavirus (HPV) affects 20 million people across the globe each year. The prevalence of HPV is vast, with the Centers for Disease Control and Prevention (CDC) reporting that at least 50% of all sexually active men and women will contract HPV at some point in their lives.¹

The most drastic and consequential effect of HPV in a carrier is the risk of developing cancer. Cervical cancer is the most commonly reported anogenital cancer; however, HPV can cause other cancers, such as vulvar, vaginal, penile, and anal. In addition to causing various types of cancer, nononcogenic HPV strains cause visible warts, specifically HPV types 6 and 11. There are more than 100 strains of HPV and approximately 30 strains affect the genital tract.²

Corresponding author: Robin Q. Olsen, MD, MPH, MS, Family Medicine/Medical Education, Virginia Tech-Carilion SOM Family Med Residency, 1314 Peters Creek Rd, Roanoke, VA 24179.

E-mail address: rjolsen@carilionclinic.org.

HPV is transmitted through skin-to-skin contact and, in the case of genital HPV specifically, sexual contact or perinatal transmission. Based on the risk of cancerous potential, genital tract HPV strains are divided into low-risk (nononcogenic) and high-risk (oncogenic) subtypes. Although visible warts do not have the same cancerous potential, they cause distress, embarrassment, and uncomfortable symptoms including itching, burning, and localized bleeding. This review article will address the diagnosis, treatment, and prevention of anogenital HPV, both low- and high-risk subtypes.

Diagnosis of genital HPV manifestations

Benign genital warts caused by HPV are diagnosed by a thorough history and physical examination. There is no widely accepted screening approach for diagnosis. Diagnos-

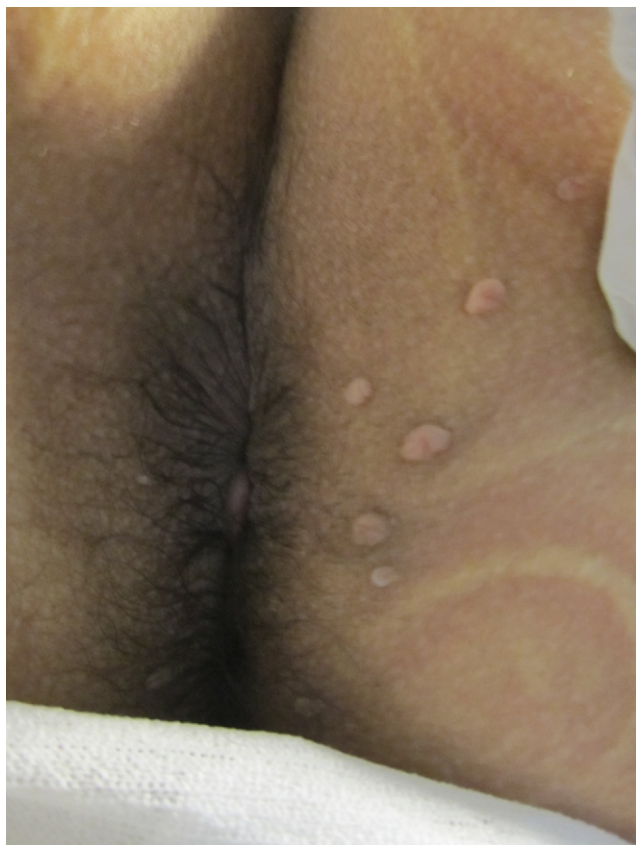

Figure 1 Anal warts on postpartum patient. Warts became prominent during pregnancy, a common phenomenon.

ing warts by biopsy and viral assays are not recommended unless the lesion looks suspicious.³⁻⁶ Genital warts usually appear as flat, pedunculated, or papular lesions (Figs. 1 and 2).⁷ They may develop anywhere in the squamous epithelium of the lower genital tract and cervix.^{5,7} Patients may present to their primary care physician with complaints of discharge, pruritus, bleeding, or burning related to underlying genital warts.⁵ The differential diagnoses for genital warts include, but are not limited to, pearly penile papules, Fordyce spots, squamous cell carcinoma, condyloma lata, molluscum contagiosum, microglandular papillomatosis, hymenal remnants, seborrheic keratoses, and fibroepitheliomas.³⁻⁷ Any lesion that looks suspicious should be biopsied. Specifically, lesions that are large, pigmented, or develop in an immunosuppressed patient deserve special attention.^{5,8} If these conditions exist, vulvar intraepithelial neoplasia (VIN) or warty vulvar cancers must be excluded.

Vulvar lesions may be cancerous or benign. This determination is made by physical examination and biopsy. Vulvar cancers in young women are more likely to be associated with HPV infection, whereas in older patients, there is less of an association with HPV than in younger women and certain types are more commonly linked with smoking, specifically keratinizing squamous cell carcinoma.^{9,10}

VIN is a premalignant lesion of the vulva. Although VIN may be HPV-related or HPV-nonrelated, HPV-related VIN is far more common. In meta-analysis of correlation be-

tween HPV infection and vulvar intraepithelial neoplasia I, approximately 93% of the pooled cases were attributed to HPV infection of any type. The most commonly found HPV strains were 6 and 11 in VIN 1, and combined were found in 41.7% of VIN 1 diagnoses.¹⁰ Premalignant VIN 3 was most commonly attributed to HPV-16, which was found in 77.7% of VIN 3 cases.¹⁰ Physical examination findings may show a lesion that is reddish, whitish, or pigmented, and is often multifocal. On biopsy, VIN shows atypical squamous epithelial cells with involvement through the entire epithelium or poorly differentiated basal cells. On the surface, a warty hyperkeratotic layer may be present.¹¹

Vaginal cancer caused by clear cell adenocarcinoma is associated with maternal diethylstilbestrol exposure (DES). Vaginal cancers of squamous cell origin are most commonly associated with HPV, but are also related to endometriosis, chronic vaginitis, prior hysterectomy, smoking and cervical irradiation.¹⁰ Vaginal intraepithelial neoplasia (VaIN) is most commonly caused by HPV and most cases are related to HPV-16, -18, -51, -56, or -66; each strain was observed in 10 to 20% of VaIN cases, with 28.6% of these cases involving multiple strains.¹⁰ Diagnosis can be made by vaginal colposcopy and biopsy of identified lesions.

Cervical lesions that may be related to HPV are detected on pap screening during well-woman examinations. It should be noted that although the association between oncogenic genital HPV infection and cervical intraepithelial neoplasias and cervical cancer is strong, there are other risk factors that lead to progression in cervical lesions, such as smoking, heredity, and immune deficiency.^{10,12} Cytological screening with pap testing serves as a triage assessment to separate lesions that are likely to have a higher risk of progression to cancer from lower-risk lesions, specifically as it relates to certain patient populations. In general, because of the high rate of HPV infection and high rate of spontaneous clearance of HPV infections and related lesions in young women (age <21 years), lower-grade cytologic findings of low-grade squamous intraepithelial lesion

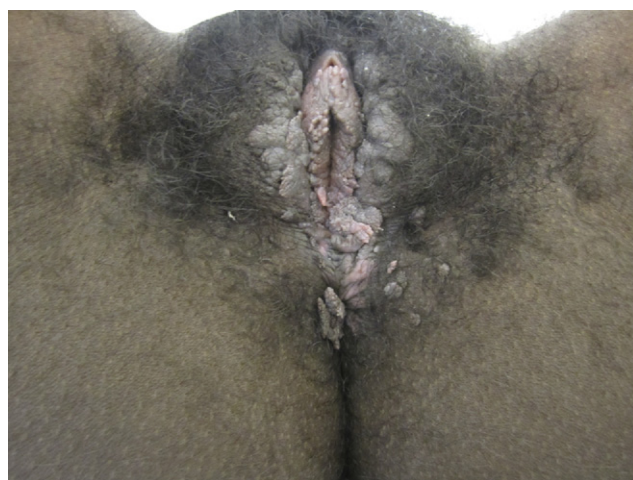

Figure 2 Anogenital warts over perineum, labia majora, and labia minora.

(LSIL) or atypical squamous cells of undetermined significance (ASCUS), which more commonly correlate with lower-grade histological findings on colposcopy, are best followed with repeat pap test after a year.¹³ It is important to note that although there is a clinical correlation between cytologic findings and histological findings, LSIL is not the same as cervical intraepithelial neoplasia grade 1 (CIN 1) and a high-grade squamous intraepithelial lesion is not the same as higher-grade cervical neoplasias (CIN 2, 3).¹² However, in a study of patients with high-grade squamous intraepithelial lesion (HSIL), findings on cytology in patients who progressed to having surgical excision, 84 to 97% were diagnosed as CIN 2 or 3 on final pathology.

In patients older than 21, determining the presence of high-risk (oncogenic) HPV adds to this cytologic triage assessment to determine who needs colposcopy and histological diagnosis. Diagnosis of high-risk HPV is made by HPV DNA testing, which uses polymerase chain reaction (PCR).¹³ The Hybrid Capture 2 Test, which is used as an adjunct to pap screening, is designed to identify 13 oncogenic HPV subtypes linked to the development of cervical cancer (subtypes 16, 18, 31, 33, 35, 39, 45, 51, 52, 56, 58, 59, 61).^{13,14} This is most commonly analyzed from the pap test itself as a reflex test when ASCUS result is found in women aged 21 to 29. In women older than 30, this test is used in addition to cytology, even with normal results. This is because studies have found that in women who were cytology-negative but HPV-16-positive, CIN 3 was discovered in 21% within 10 years' follow-up. In those positive for HPV-18, 18% developed CIN 3 within 10 years' follow-up. As a result, high-risk HPV discovered on DNA screening (even when cytology is negative) in women older than 30 is followed with a repeat test and cytology at 12 months. If high-risk HPV is still present after 12 months, even with normal repeat cytology, colposcopy is recommended.¹³ In women younger than 21, HPV testing should not be used because of high rates of HPV presence and high rates of spontaneous regression.

Treatment of genital HPV manifestations

The treatment of HPV-related genital warts is focused at removing warts that are symptomatic.³⁻⁵ There is no evidence that the treatment of warts affects the transmission of HPV.⁶ In treating symptomatic warts, the immune system can actually be stimulated to suppress further growth. Untreated lesions can resolve spontaneously, grow larger, or remain stable in size over time.^{3,5} In 2006, the CDC recommended that the treatment of genital warts should be guided by patient preference.⁷

The two main treatment approaches to genital warts include nonsurgical vs surgical intervention.^{5,6} Both approaches treat warts but do not cure the virus that causes them.³ The nonsurgical modalities can either be patient- or physician-applied. No treatment modality has been proven

vastly superior to another.⁶ However, a new treatment modality is recommended if there is no response after three treatment cycles with current modality.³ The choice of therapy is based on several factors, including cost, convenience, location of lesion, and physician experience.^{3,5}

Patient-applied, nonsurgical treatment modalities include podophyllotoxin, imiquimod (Aldara, 3M Pharmaceuticals, Northridge, CA) and sinecatechins 15% ointment (Veregen, PharmaDerm, Florham Park, NJ). The use of interferon and 5-fluorouracil (Efudex, Valeant Pharmaceuticals International, Mississauga, ON, Canada) is no longer recommended because of side effects and lack of advantage over other modalities.^{3,7} The use of patient-applied modalities has been supported because of its promotion of privacy, which may lead to less psychological distress.⁵ Podophyllotoxin is an antimetabolic agent that induces local tissue necrosis.⁶ It is applied twice per day for three days for two to four cycles. It is not recommended for lesions involving the vagina, urethra, rectum, and anal areas because of potential side effects.^{3,15,16} Podophyllotoxin trials reviewed showed 43 to 77% cure rates with treatment of between 3 to 4 weeks' time.^{15,16} Recurrence also varied widely by study, and in looking at a meta-analysis that pooled 9 clinical trials evaluating podophyllotoxin and 9 trials evaluating imiquimod, cure rates of the pooled data were found to be 56.4% with podophyllotoxin and 50.3% with imiquimod.¹⁷ There was no statistical significance between these groups and side effect profile was less favorable in the podophyllotoxin studies examined.¹⁷ Imiquimod works by stimulating the innate and cell-mediated immune system, leading to cytokine production. It is applied at bedtime three times per week and can be used for up to three months or longer, usually for 16 weeks in most studies.^{4,17} Success rates with the imiquimod cream vary in individual trials from 37 to 54% complete clearance.¹⁸⁻²⁰ Unfortunately, clinical recurrence is between 13 and 19%.^{18,19}

The newest patient-directed therapy is Veregen (sinecatechins 15% ointment US name, Polyphenon E European trade name), which is compounded from green tea extract using eight different catechins. Catechins are shown to inhibit tumor invasion via antiangiogenic activity. Sinecatechins 15% ointment is applied three times daily for 16 weeks in trials and has shown complete clearance in up to 53 to 54.9% of patients, depending on the study.^{21,22} More impressive is the finding that in those who achieved complete clearance, only 4 to 6.5% experienced relapse of lesions.^{21,22}

A cost analysis comparison between sinecatechins 15% and imiquimod showed sustained clearance of 51.9% vs 40.6%, which led to a nearly \$800 projected cost savings over imiquimod for each first line use clearance.²³

Physician-applied nonsurgical modalities include podophyllin resin and trichloroacetic acid (TCA). However, in Europe podophyllin resin is no longer recommended in primary care because of its systemic effects because it is systemically absorbed, very neurotoxic, and can induce bone marrow suppression.^{5,6} It appears to be most effective on small, moist lesions. TCA works by chemical cautery

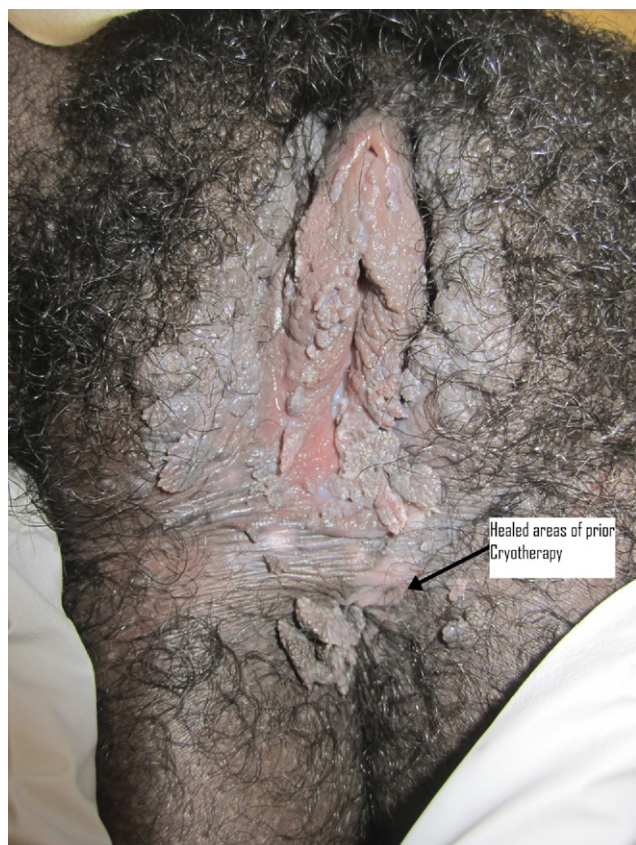

Figure 3 Same patient with areas (arrow) of pink healed skin from prior cryotherapy treatments.

when a small amount is applied to visible warts. TCA has been criticized because of its propensity to damage healthy skin.^{6,8} However, a study completed in Turkey, showed that if normal skin was protected with paraffin or other neutralizing substances with a smaller amount of TCA applied, side effects were much more mild. TCA was found to be successful and safe in women with mild to moderate warts if those precautions were taken, with 100% success rate and 17.6% recurrence.²⁴

Surgical modalities include cryotherapy (Figs. 3 and 4), electrocautery, laser therapy, and surgical excision. All modalities can lead to discomfort, erythema, erosion, ulceration, depigmentation, or scarring.⁵ Cryotherapy is generally recommended for a small to medium number of warts. It may also be preferred for meatal lesions, and during pregnancy.^{6,8} Nitrous oxide and liquid nitrogen are both used as agents for cryotherapy.⁷ A cryoprobe, spray, or cotton-tipped applicator can be used to perform cryotherapy.⁵ Electrocautery uses electrocautery or coagulation to destroy HPV-affected tissue.⁸ In general, laser or excision modalities are reserved for treatment of large lesions or obstructive lesions in the urethra and vagina.⁵ Laser therapy uses focused infrared light to destroy a wart, and can be used for all HPV lesions.^{8,13} Cosmetic results are usually very good when depth is controlled; however the cost is prohibitive.¹² Surgical excision has been advocated for women with very few warts.⁸ Surgical excision has com-

parable success rates of 35 to 72% and recurrence is common and seen in 19 to 29% of those treated with excision.⁶

Treatment for VIN includes imiquimod cream as a patient-applied modality and surgical excision (via local excision or superficial vulvectomy), loop electrosurgical excision (LEEP), or CO₂ laser vaporization as physician-applied modalities. In a study following these modalities on 50 patients with biopsy-confirmed VIN 2 or 3, surgical excision with local excision or vulvectomy was associated with the highest complete response (77%) with a low rate of recurrence (9.1%) among those with a complete response. Patient-applied imiquimod had the lowest complete response (33%) but no recurrences within those with complete response. Laser vaporization had similar results. This study was limited by the small numbers in treatment arms ranging from nine patients in the imiquimod group to 14 patients in the LEEP group.¹¹

In cases of high-risk HPV, which lead to abnormal cervical findings, treatment should follow American Society for Colposcopy and Cervical Pathology (ASCCP) guidelines based on the cytological and histologic findings.^{12,13} In general, higher-grade cytological findings are referred for histologic diagnosis through colposcopy and biopsy, whereas cytology associated with low-grade lesions are followed with close clinical follow-up. Once histologic diagnosis of CIN 2 or 3 is made by colposcopy, depending on the case, ablative or surgical excision procedures are rec-

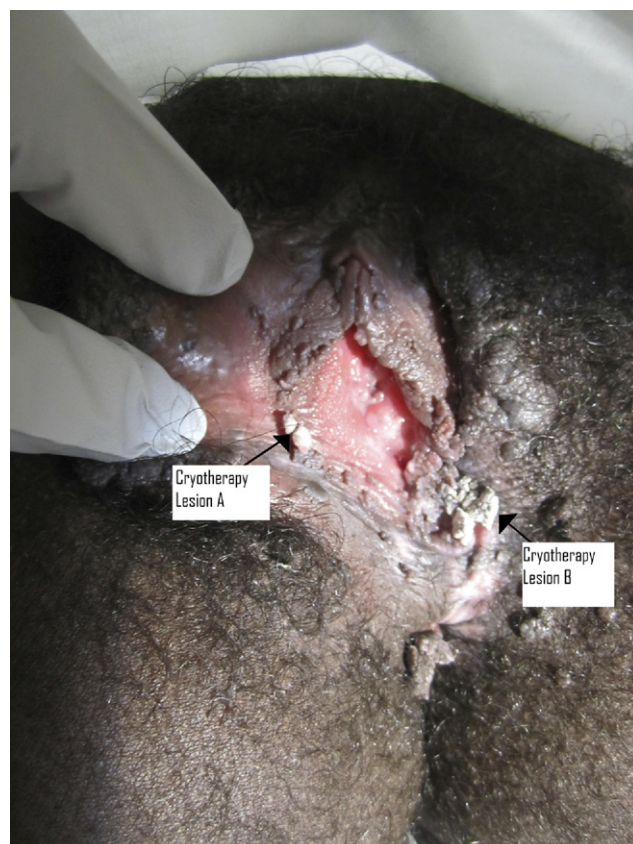


Figure 4 Same patient undergoing cryotherapy of two irritating areas (arrows). Note whitening of warts from cryotherapy.

ommended. Ablative therapies work by destroying the affected tissue but do not allow for a tissue sample for pathology. These methods include laser ablation, cryotherapy, cold coagulation, and electrofulguration.

Surgical excision procedures include LEEP, cold-knife conization, electrosurgical needle conization, and laser conization. All modalities have been found to have similar failure rates between 5 and 15% without statistically significant differences in response rates.^{12,13}

If the lesion extends into the endocervical canal on the endocervical curettage (ECC) sampling during colposcopy, or the transformation zone cannot be completely visualized on colposcopy, surgical excisional procedures are recommended because ablative measures will not allow for histological confirmation of clear margins. When the ECC is negative for histologic abnormality and colposcopy is considered adequate, ablative measures may be preferred to surgery because surgical procedures are associated with increased risk of preterm delivery, premature membrane rupture, and low birth weight in subsequent pregnancies.¹² However, there are insufficient studies to rule out small pregnancy effects from ablative therapies and treatment preference should weigh fertility considerations as well as risk of missed lesion, patient preference, and age. Currently, there are no Food and Drug Administration–approved non-surgical treatments of cervical neoplasia, but an oral medication, diindolylmethane (DIM), is in an ongoing trial. One study enrolling 64 subjects demonstrated a colposcopic improvement in 25 of the 45 patients of the DIM treatment group (56%). Follow-up was through six months post treatment and this was the only study available for review.²⁵

Prevention of genital HPV

Perinatal transmission is possible, but rare. The only sure way to prevent sexual spread of HPV is abstinence. Condoms reduce the risk of transmission, but because skin-to-skin contact is cause of spread, condoms are not as effective in the prevention of HPV as is the case for other sexually transmitted infections. Different studies evaluating effectiveness of male condom use in HPV prevention have reported conflicting results; however, more recent studies have shown that correct and consistent use of male condoms by a partner reduces the chance of transmission to the female partner by 70%.²⁶

The best way to prevent cervical cancer and high-risk HPV complications is to have organized, scheduled, gynecological screenings with proper therapy and treatment of precancerous lesions. However, for developing countries, screenings may not be practical or available. Vaccines such as Gardasil (HPV vaccine quadrivalent; Merck & Co., Whitehouse Station, NJ) and Cervarix (HPV vaccine bivalent; GlaxoSmithKline, London, UK) are especially needed in these types of populations to reduce the prevalence of cervical cancer because access to physicians is limited.²⁷

Cervarix is relatively new to the United States; it just received its FDA approval on October 16, 2009. It is indicated for the prevention of cervical cancer caused by HPV types 16 and 18, as well as for the prevention of CIN and adenocarcinoma.²⁸ Cervarix does not help protect against all forms of HPV, only types 16 and 18. However, approximately 70% of all cervical carcinomas contain these two types. If the patient has already been exposed to these types of HPV, there may not be much effectiveness in taking the vaccine. Cervarix has not been indicated for the prevention of genital warts. The only known contraindication for Cervarix is hypersensitivity to objects within the vaccine and to latex.

Gardasil is a vaccine to guard against four different types of HPV: 6, 11, 16, and 18.²⁹ The indications for Gardasil are for the prevention of HPV types 6, 11, 16, and 18 in females aged 9 to 26 years old. It is used in the prevention of cervical, vulvar, and vaginal cancer caused by HPV types 16 and 18, genital warts (condyloma acuminata) caused by HPV types 6 and 11, and precancerous or dysplastic lesions caused by HPV types 6, 11, 16, and 18.³⁰ By preventing the formation of HPV types 6, 11, 16, and 18, it also helps in the prevention of CIN, cervical adenocarcinoma, and VIN.²⁹ Results from a phase III study in men show that Gardasil prevented 90% of external genital lesions caused by HPV types 6, 11, 16, and 18.³¹ In a more recent study published that enrolled 4065 males aged 16 to 26 years, the quadrivalent vaccine prevented 60.2% of lesions in males vs the placebo group.³²

Because Gardasil and Cervarix are considerably new, studies for long-term efficacy are currently unavailable. The efficacy of Cervarix has been proven to last for 6.4 years. Gardasil's efficacy has been shown to last for as many as five years.³³

Conclusion

Different forms of human papillomavirus are responsible for anogenital cancers as well as benign lesions and warts, which cause distress and embarrassment. For primary care physicians, new modalities must be constantly compared against older methods, with the proper risks and benefits for treatments evaluated. Understanding treatment and prevention of HPV allows for proper care, prevention, and counseling for patients and reduces the public health burden this disease imposes. The purpose of this review is to provide new updates on treatment as well as covering old methods and prevention for the primary care physician.

Acknowledgments

The authors would like to thank our health sciences librarian Jane Burnette for her assistance with obtaining copies of original articles needed for this publication.

References

1. [Womenshealth.gov: Human papillomavirus \(hpv\) and genital warts](http://www.womenshealth.gov/faq/human-papillomavirus.cfm#top). 2009. Available at: <http://www.womenshealth.gov/faq/human-papillomavirus.cfm#top>. Accessed June 19, 2010.
2. Stanley M: Prospects for eradication of ano-genital neoplasia. *Med Virol* 16:139-149, 2006
3. Kodner CM, Nasraty S: Management of genital warts. *Am Fam Physician* 70:2335-2342, 2004
4. O'Mahony C: Genital warts current and future management options. *Am J Clin Dermatol* 6:239-243, 2005
5. Gunter J: Genital and perinatal warts: new treatment opportunities for human papillomavirus infection. *Am J Obstet Gynecol* 289:S3-S11, 2003
6. Wiley DJ, Douglas J, Beutner K, et al: External genital warts: diagnosis, treatment, and prevention. *Clin Infect Dis* 35(Suppl 2):S210-S224, 2002
7. Mayeaux EJ Jr, Dunton C: Modern management of external genital warts. *J Low Gen Tract Dis* 12:185-192, 2008
8. Ault KA: Human papillomavirus infections: diagnosis, treatment, and hope for a vaccine. *Obstet Gynecol Clin North Am* 30:809-817, 2004
9. Garland SM, Insinga RP, Sings HL, et al: Human papillomavirus infections and vulvar disease development. *Cancer Epidemiol Biomarkers Prev* 18:1777-1784, 2009
10. Insinga RP, Liaw K, Johnson LG, et al: A systematic review of the prevalence and attribution of human papillomavirus types among cervical, vaginal, and vulvar precancers and cancers in the United States. *Cancer Epidemiol Biomarkers Prev* 17:1611-1622, 2008
11. Bruchim I, Gotlieb WH, Mahmud S, et al: HPV-related vulvar intraepithelial neoplasia: outcome of different management modalities. *Int J Gyn Obstet* 99:23-27, 2007
12. Wright TC, Massad S, Dunton, et al: CJ2006 consensus guidelines for the management of women with cervical intraepithelial neoplasia or adenocarcinoma in situ. *Am J Obstet Gynecol* 197:340-345, 2007
13. Wright TC, Massad S, Dunton, et al: CJ2006 consensus guidelines for the management of women with abnormal cervical screening tests. *Am J Obstet Gynecol* 197:346-355, 2007
14. Gravitt PE, Jamshidi R: Diagnosis and management of oncogenic cervical human papillomavirus infection. *Infect Dis Clin North Am* 19:439-458, 2005
15. Von Krogh G: Topical treatment of penile condylomata acuminata with podophyllin, podophyllotoxin and colchicine. A comparative study. *Acta Derm Venereol* 58:163-168, 1978
16. Von Krogh G, Hellberg D: Self-treatment using a 0.5% podophyllotoxin cream of external genital condylomata acuminata in women. A placebo-controlled, double-blind study. *Sexually Transmitted Diseases* 19:170-174, 1992
17. Yan J, Chen SL, Wang HN, et al: Meta-analysis of 5% imiquimod and 0.5% podophyllotoxin in the treatment of condylomata acuminata. *Dermatology* 213:218-223, 2006
18. Beutner KR, Spruance SL, Hougham AJ, et al: Treatment of genital warts with an immune-response modifier (imiquimod). *J Am Acad Dermatol* 38:230-239, 1998
19. Edwards L, Ferenczy A, Eron L, et al: Self-administered topical 5% imiquimod cream for external anogenital warts. *Arch Dermatol* 134:25-30, 1998
20. Maitland JE, Maw R: An audit of patients who have received imiquimod cream 5% for the treatment of anogenital warts. *Int J STD AIDS* 11:268-270, 2000
21. Tatti S, Stockfleth E, Beutner KR, et al: Polyphenon E®: a new treatment for external anogenital warts. *Br J Dermatol* 162:176-184, 2010
22. Stockfleth E, Beti H, Orasan R, et al: Topical Polyphenon® E in the treatment of external genital and perianal warts: a randomized controlled trial. *Br J Dermatol* 158:1329-1338, 2008
23. Langley PC: A cost-effectiveness analysis of sinecatechins in the treatment of external genital warts. *J Med Econ* 13:1-7, 2010
24. Taner Z, Taskiran C, Onan AM, et al: Therapeutic value of trichloroacetic acid in the treatment of isolated genital warts on the external female genitalia. *J Reprod Med* 52:521-525, 2007
25. Del Priore G, Gudipudi DK, Montemarano N, et al: Oral diindolylmethane (DIM): pilot evaluation of a non surgical treatment for cervical dysplasia. *Gynecol Oncol* 116:464-467, 2010
26. Winer RL, Hughes JP, Feng Q, et al: Condom use and the risk of genital human papillomavirus infection in young women. *N Engl J Med* 354:2645-2654, 2006
27. Kawana K, Yasugi T, Taketani Y: Human papillomavirus vaccines: current issues and future. *Indian J Med Res* 130:341-347, 2009
28. Cervarix FDA package insert. Available at: <http://www.fda.gov/downloads/BiologicsBloodVaccines/Vaccines/ApprovedProducts/UCM186981.pdf>. Accessed August 25, 2010.
29. Paavonen J, Naud P, Salmeron J, et al: Efficacy of human papillomavirus (HPV)-16/18 AS04-adjuvanted vaccine against cervical infection and precancer caused by oncogenic HPV types (PATRICIA): final analysis of a double-blind, randomized study in young women. *Lancet* 374:301-314, 2009
30. Garland S, Hernandez-Avila M, Wheeler C, et al: Quadrivalent vaccine against human papillomavirus to prevent anogenital diseases. *N Engl J Med* 356:1928-1943, 2007
31. Science eyes HPV vaccine use in men—will shot be approved for U.S. males? Vaccine prevented 90% of external genital lesions caused by 4 HPV types. *Contraceptive Technology Update* 30:85-88, 2009
32. Giuliano AR, Palefsky JM, Goldstone S, et al: Efficacy of quadrivalent HPV vaccine against HPV infection and disease in males. *N Engl J Med* 364:401-411, 2011
33. Harper D: Currently approved prophylactic HPV vaccines. *Exp Rev Vaccines* 8:1663-1679, 2009